

CLOSURE OF CORONARY ARTERY FISTULA AND CORRECTION OF OCCLUDED LEFT CIRCUMFLEX ARTERY WITH COVERED STENT SIMULTANEOUSLY

Muzaffar Ali¹, Ahsan Iqbal², Zubair Akram³

¹⁻³ Department of Cardiology, Allama Iqbal Medical College-Jinnah Hospital, Lahore-Pakistan

Address for Correspondence:

Dr. Muzaffar Ali,

Assistant Professor,

Department of Cardiology, Allama Iqbal Medical College-Jinnah Hospital, Lahore-Pakistan

Email: mzra750@hotmail.com

Date Received: December 16, 2013

Date Revised: March 19, 2014

Date Accepted: March 22, 2014

Contribution

All the authors contributed significantly to the research that resulted in the submitted manuscript.

All authors declare no conflict of interest.

ABSTRACT

We report a case of closure of coronary artery fistula and opening of total occlusion of left circumflex artery (LCX) with polytetrafluoroethylene (PTFE) covered stent. In this case report a 50 year old hypertensive and smoker male, had coronary artery fistula from LCX to pulmonary artery and there was totally occluded LCX which continued as obtuse marginal branch(OM). The fistula was closed and LCX opened simultaneously with PTFE covered stent. This successful experience suggested that covered stent is a feasible and safe alternative to catheter based devices in the closure of coronary artery fistula. Though long term evaluation is needed.

Key Words: Coronary Artery Fistula, Coronary Artery Disease, PTFE Covered Stent

INTRODUCTION

Coronary artery fistula is among the rare diseases but can cause significant complications. Coronary artery fistula incidence is 0.002% in the overall population. It is defined as an abnormal communication between the coronary and any cardiac chamber or any segment of systemic or pulmonary circulation. Coronary artery fistula can be seen as incidental finding in 0.3% to 0.8% of patients undergoing diagnostic coronary angiography.^{1,2}

The right coronary artery and its branches is the commonest site of origin of coronary artery fistulas (constituting 55% of cases) and the second commonest site is the left coronary artery (about 35% of cases). Low pressure heart chambers or great vessels are commonest drainage sites of these fistulas. Fistulous drainage occurs into the right ventricle in 41%, right atrium in 26%, pulmonary artery in 17%, left ventricle in 3% and coronary sinus in 7%.³

Coronary artery fistulas are usually congenital but other causes include traumatic and iatrogenic. Coronary artery fistulas are often asymptomatic. However, in symptomatic patients the fistula can cause various symptoms such as lethargy, fatigue, shortness of breath on exertion and even angina through Coronary Steal Phenomenon.⁴

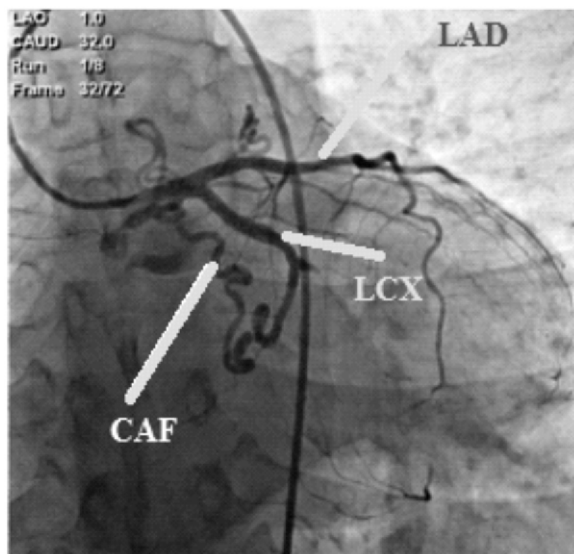
Coronary artery fistula closure is offered if it has a significant shunt or the patient is symptomatic. Coronary artery fistula can be closed successfully by surgery.⁵ Percutaneous catheter based closure has also shown to be as effective as surgical closure. It can be done by detachable balloons, coils, umbrella devices, polyvinyl alcohol foam and recently with covered stents.⁶

CASE REPORT

A 50-years- old male, hypertensive for 2 years on losartan and amlodipine with good control of blood pressure and he was well compliant with medication. He was smoking ten cigarettes daily for last 3 years. He presented with recurrent episodes of chest pain lasting for half hr for 5 days until his pain intensity , frequency and duration increased for last 24 hrs .He was admitted in cardiac emergency on 16th July 2013. Blood pressure was 135/84 mmHg and pulse was 75/min. The EKG showed small q waves with T wave inversion in inferior leads. Cardiac biomarkers were elevated like CPK 650 U/L and CPK- MB was 110 U/L. were raised. Echocardiogram revealed dilated LV with fair LV systolic function and posterolateral wall hypokinesia. Acute coronary syndrome was the clinical diagnosis.

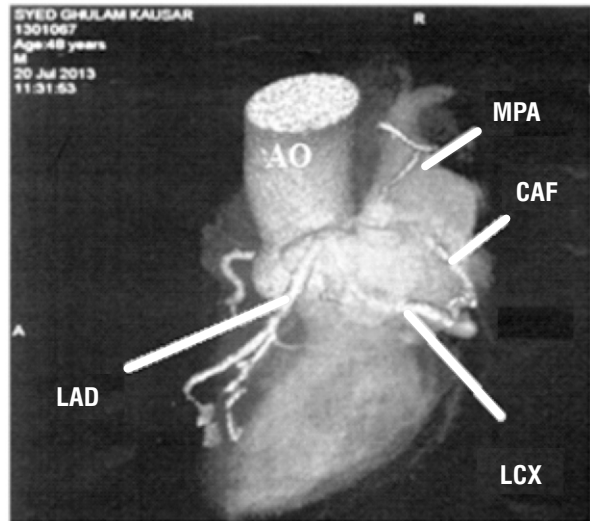
The coronary angiogram in the antero-posterior(AP) caudal and right anterior oblique (RAO) caudal projection shows the coronary artery fistula(CAF) originating from the AV branch of Left Circumflex Artery. It passes anteriorly with tortuous and serpiginous course to the main pulmonary artery. The large OM1 showing total proximal occlusion distal to origin of coronary artery fistula (Figure 1). Left anterior descending and right coronaries show mild irregularities.

Figure 1: Coronary Angiogram Showing Fistula Arising from LCX and Total Occlusion of OM



After incidental finding of coronary artery fistula at angiography we proceeded with CT angiogram to look for the track and distal entry of the coronary artery fistula. CT angiogram showed a coronary artery fistula arising from LCX and draining into pulmonary artery (Figure 2A & B).

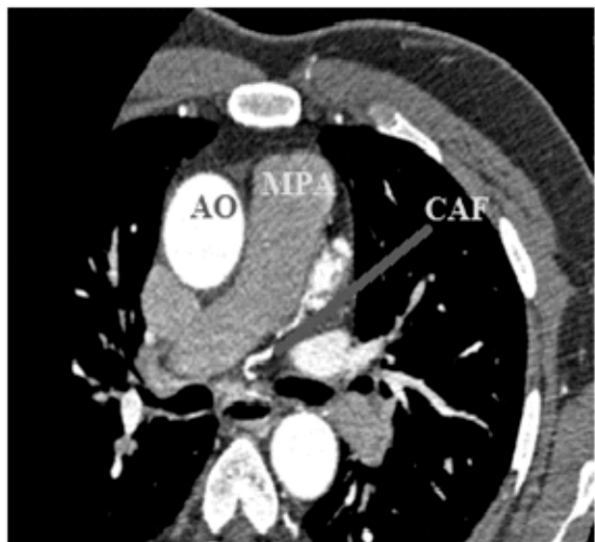
Figure 2A: CT Angiogram, Arrows Showing the Coronary Artery Fistula



Right heart catheterization was done to quantify the severity of shunt and to see whether there was any step up of oxygen saturation in the pulmonary artery. It showed QP/QS of 1.5 which indicates moderate shunt and the step up of oxygen saturation in pulmonary artery. The oxygen saturation of the right ventricle was 70% and that of pulmonary artery was 80%.

Based on the above mentioned findings, we decided to occlude the coronary artery fistula and open the LCX artery

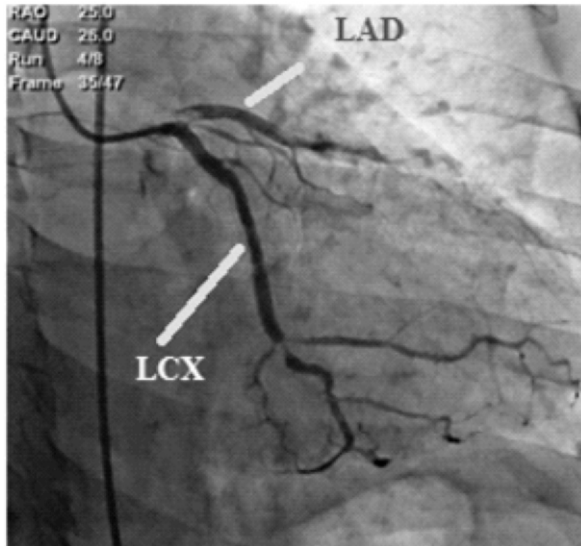
Figure 2B: CT Angiogram , Showing Track of Fistula and Entry into Pulmonary Artery



simultaneously. For this, we preferred percutaneous closure of coronary artery fistula and simultaneously opening of occluded OM Branch with PTFE covered stent. After predilatation of the lesion by conventional balloon (2x10 mm), a 3.0 x 27 mm covered stent (aneugraftDx) was deployed at 16 atm for 20 seconds covering the coronary artery fistula and the occluded OM branch of LCX.

Post stent dilatation was carried out with 3.5x8mm Quantum Maverick non-compliant balloon at 20 atm for 20 seconds to maximize the final luminal diameter. Final check injection revealed no residual stenosis at stented site with TIMI III flow into distal LCX and there was complete sealing of the coronary artery fistula at its origin and no residual shunt or flow (Figure 3).

Figure 3: Coronary Angiogram After Implantation of Covered Stent with Complete Sealing of CAF and no Residual Shunt and Successful Opening of Occluded OM Branch



The anti-platelet regimen Aspirin 300mg, Clopidogrel 150 mg was prescribed for 4 weeks and then dual anti-platelet therapy Aspirin 75 mg and Clopidogrel 75 mg for 1 year. Two days after the procedure the patient was discharged without any complication and follow-up was planned which included follow-up angiography at 6 months for late results.

DISCUSSION

Coronary artery fistula is a rare disease but can cause significant symptoms. Surgical closure of coronary artery fistula has shown to be very effective. In the recent years, there is an increased trend towards percutaneous closure of the coronary artery fistula with catheter based techniques.

The results of catheter based closure have been very promising. Coils, detachable balloons, Umbrella devices

have been used effectively.⁷ More recently covered stents have proven to be beneficial in coronary artery fistula closure. The selection of the device for percutaneous closure depends upon the morphology of the fistula, its feeding vessel morphology.

Covered stent implantation is much easier and timesaving as compared to coiling or surgery. The complications of covered stent implantation can be side branch occlusion that can cause myocardial infarction if there is a big side branch in vicinity of fistula and stent thrombosis or in-stent re-stenosis (ISR).

In our case we preferred closure of the coronary artery fistula with PTFE covered stent. The reason for the selection of covered stent included favorable anatomy of the feeding vessel as it was not tortuous, the angulation of ostium of fistula was not acute and there was no sizeable branch arising from LCX in the vicinity of coronary artery fistula. The other thing that prompted the use of covered stent was that there was disease in the LCX in the vicinity of fistula that was causing occlusion of OM branch of LCX. Compared with coil embolization, using covered stent to treat CAF was technically easier and more timesaving. It did not require the fistula to be cannulated and wired. In addition, there were no concerns over multiple drainage sites, tortuosity of the feeding vessel, angulation of the fistula ostium and pulmonary artery embolization and coil recoil.

Covered stent has been initially used in the field of peripheral vascular intervention. It has also been used in treating vascular perforations and dissections in coronary arteries lately. There is a trend towards extending its utilization in various other indication such as closure of coronary artery fistula by covered stents. However, there is very limited data available for usage of covered stents in closure of coronary artery fistula and there are only a few case reports.

He et al, successfully treated a coronary artery fistula arising from the proximal segment of Left Anterior Descending artery (LAD) using covered stent while simultaneously stenting stenosis in the middle segment of LAD.⁶

Similarly, Arfahetal, successfully treated Right Coronary Artery (RCA) fistula with percutaneous transcatheter technique using covered stent.⁷

Kassanian et al, described a case with 3 coronary artery fistulas that were draining in the pulmonary artery. Two of the fistulas arose from proximal and mid LAD and one fistula arose from RCA. All of these fistulas were successfully closed by covered stent implantation at the origin of their ostium.⁸

Mullasari et al, documented a case of 40 years old man with multiple coronary artery fistulas arising from septal branches of LAD draining into pulmonary artery. The patient was successfully treated by covered stent implantation in LAD that covered the septal branches feeding the fistula.⁹

CONCLUSION

In conclusion, our experience with PTFE covered stent in the closure of coronary artery fistula in this patient has been remarkable. Though further studies and longer follow-up is required to see the efficacy of covered stents in closure of coronary artery fistula. Hence, covered stents can be used in selected patients with coronary artery fistula who have suitable morphology.

REFERENCES

1. Angelini P, Velasco JA, Flamm S. Coronary anomalies: incidence, pathophysiology, and clinical relevance. *Circulation* 2002;105:2449-54.
2. Vavuranakis M, Bush CA, Boudoulas H. Coronary artery fistulas in adults: incidence, angiographic characteristics, natural history. *Cathet Cardiovasc Diagn* 1995;35:116-20.
3. Schamroth C. Coronary artery fistula. *J Am Coll Cardiol* 2009;53:523.
4. Cheung DL, Au WK, Cheung HH, Chiu CS, Lee WT. Coronary artery fistulas: long-term results of surgical correction. *Ann Thorac Surg* 2001;71:190-5.
5. Armsby LR, Keane JF, Sherwood MC, Forbess JM, Perry SB, Lock JE. Management of coronary artery fistulae: patient selection and results of transcatheter closure. *J Am Coll Cardiol* 2002;39:1026-32.
6. He Y, Park JH, Kim YH, Lee SW, Lee JW, Hong MK, et al. Closure of coronary artery fistula with covered stent and correction of stenosed left anterior descending artery in the same procedure. *Korean Circ J* 2004;34:100-3.
7. Arfahetal MR. Closure of coronary artery fistula using covered stent. *J Saudi Heart Assoc* 2005;17:3.
8. Kassaian SE, Mahmoodian M, Salarifar M, Alidoosti M, Abbasi SH, Rasekh A. Stent-graft exclusion of multiple symptomatic coronary artery fistulae. *Tex Heart Inst J* 2007;34:199-202.
9. Mullasari AS, Umesan CV, Kumar KJ. Transcatheter closure of coronary artery to pulmonary artery fistula using covered stents. *Heart* 2002;87:60.