

ACUTE MYOCARDIAL INFARCTION ASSOCIATED WITH THYROTOXICOSIS

Madhu Gupta¹, DipeshPradhan², SunJian³, Lipingchen⁴, Xiao Fei⁵, Bhojraj Sharma⁶

¹⁻⁶Department of Cardiology, Norman Bethune College of Medicine,

Address for Correspondence:

Dr.Madhu Gupta

Department of Cardiology, Norman Bethune College of Medicine, The first Bethune Hospital of Jilin University, Changchun 130021, PR China.

E-mail: madhugupta.md@gmail.com

Date Received: January 02, 2013

Date Revised: February 07, 2013

Date Accepted: March 10, 2013

Contribution

All the authors contributed significantly to the research that resulted in the submitted manuscript.

All authors declare no conflict of interest.

ABSTRACT

Objective: Thyrotoxicosis is the endocrine disorder which increases oxygen demand and at the same time can induce coronary vasospasm leading to acute myocardial infarction. Patients with thyrotoxicosis induced acute myocardial infarction are rare. The exact mechanism is still not known. The patients with painless thyroiditis shows thyrotoxic phase during early phase which is the main culprit for changes in cardiovascular hemodynamic and acute myocardial infarction. Here, we present a 23 year old male patient without any risk factors of cardiovascular disease presenting with acute myocardial infarction induced by thyrotoxicosis due to painless thyroiditis.

Key Words: Acute myocardial infarction; Thyrotoxicosis; Normal coronary arteries.

INTRODUCTION

Acute Myocardial Infarction (AMI) is a condition where circulation to the heart is compromised. The AMI is triggered by increased oxygen demands (such as fever, thyrotoxicosis), hyperlipidemia, hyper coagulation states, obesity, smoking and cocaine abuse. Myocardial infarction with normal coronary arteries associated with iatrogenic hyperthyroidism can be possibly life-threatening^{1,2} The most common cardiovascular manifestations of thyrotoxicosis have been recognized as angina pectoris, atrial fibrillation, myocardial infarction and heart failure³. We present a very interesting case report of an acute myocardial infarction induced by thyrotoxicosis with painless thyroiditis without coronary stenosis.

CASE REPORT

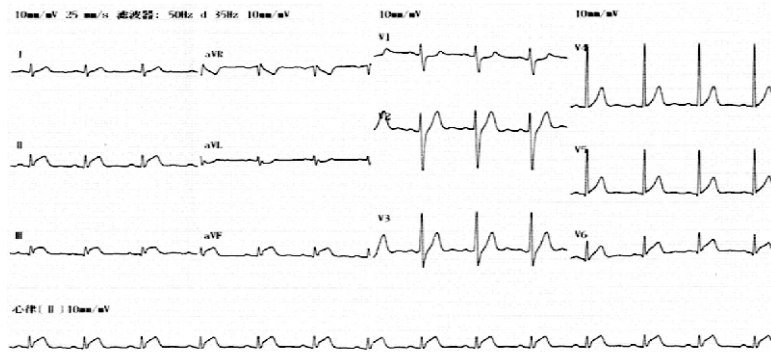
A 23 years old male came to the emergency department with intermittent squeezing type of central chest pain and sweating for last three days. There was no history of palpitations, tremors, heat intolerance, fever, cough, expectoration or dyspnea. The patient's weight was normal (BMI-22.7) and he denied any previous and family history of hypertension, diabetes mellitus, hyperlipidemia or any others systemic or cardiovascular diseases. He did not use drugs or alcohol, and except for a history of smoking cigarette quarter of pack per year, he had healthy attributes. On physical examination, the patient was conscious, afebrile,

pulse rate of 90 beats per minute, blood pressure of 162/94 mmHg, respiratory rate 18 times per minute with normal jugular venous pressure and carotid pulse. The head and neck examination were normal, no exophthalmos. Heart auscultation revealed audible first and second heart sound with no additional sounds. The chest and others systemic examinations were normal. Standard eighteen leads electrocardiogram (ECG) showed ST -segment elevation (0.2mv) in the inferior leads(II, III, aVF), ST- segment depression (0.1mv) in 3R-5R and ST segment elevation (0.1mv) in posterior wall leads (V7-V9) as shown in fig.1 and 2 which is consistent with inferior and posterior wall AMI. We diagnosed the case as AMI and treated with aspirin, clopidogrel, sublingual nitroglycerine and beta-adrenergic blockers to maintain myocardial normal cell metabolism. The cardiac enzymes was elevated with Myoglobin 147.0ng/ml, TroponinI11.10ng/ml (Normal:0-0.034ng/ml) and CK - MB27.70ng/ml (Normal:0.6-6.4ng/ml). Echocardiography findings showed normal with EF-54%. Emergency coronary angiography was performed which

showed normal without significant coronary arteries stenotic lesions. We assumed that the AMI caused by coronary spasm. Thyroid function test revealed Thyroxin(fT4) 7.2pmol/l(Normal:3.1-6.8pmol/l), Triiodothyronine (fT3)33.76pmol/l(Normal:12.0-22.0pmol/l)and Thyroidstimulatinghormone (TSH) 0.034 μ IU/ml (Normal:0.274-2.2 μ IU/ml),Thyroglobulin2.50ng/mL(Normal:1.4-78.0ng/mL)andThyroglobulinantibody 10.97IU/mL (Normal:<115.0IU/mL) which was suggestive of thyrotoxicosis. AnI131thyroid scan showed decreased uptake suggesting thyroiditis. Thyroid sonogram showed bilateral sub-mandibular and bilateral cervical lymph node enlargement.

After few days of admission, chest pain subsided. Repeat thyroid function test after a week showed normal T3 and T4 but decreased TSH level with 5.28pmol/l, 20.32pmol/L and 0.1 μ IU/ml respectively. Thyroid function test findings suggestive of subclinical hyperthyroidism and hence advised for repeat T3, T4 and TSH after one month.

Figures 1: ECG shows segment elevation (0.2mv)in inferior leads(II,III, aVF



Figures 2: ST-segments depression in lead 3R-5R and ST-segment elevation in posterior leads (V7-V9)

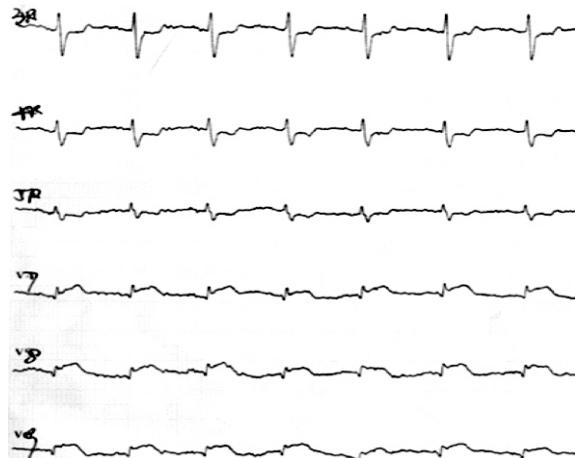
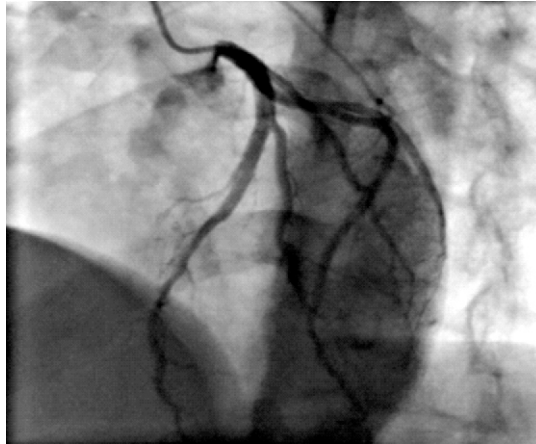



Figure 3: Coronary Angiography showed normal coronary arteries**Figure 4: Thyroid Scan**

DISCUSSION

Myocardial infarction induced by thyrotoxicosis, is rare with incidence of only 1.8%. However the trend is going towards upward direction⁴. The possible causes of acute myocardial infarction in thyrotoxic patients with normal coronary arteries are unclear. Several mechanisms have been proposed for AMI with thyrotoxicosis such as temporary major coronary artery occlusion, small vessel disease and increased myocardial oxygen demand⁵.

The direct metabolic effect of thyroid hormone in the myocardium is secondary to supraventricular tachycardia or atrial fibrillation or atrial flutter or coronary spasm^{2,4,6}. The abnormalities of the coagulation system have been reported in patients with thyrotoxicosis. Thromboembolism usually occurs in thyrotoxic patients with accompanying atrial fibrillation or congestive heart failure. Erem et al reported increased levels of plasma fibrinogen and several

coagulation factors, von Willebrand factor, antithrombin, and PAI-1 and decreased levels of t-PA in patients with overt hyperthyroidism⁷. Thyrotoxic stage can influence cardiovascular hemodynamics by increasing heart rate, cardiac contractility, cardiac output, and decreasing systemic vascular resistance. Thyrotoxic stage is a hyperadrenergic state, where there is increased adrenergic receptor sensitivity and an increased number of receptors, which leads to stimulation of adrenergic receptors on coronary arteries. This may further provoke coronary vasospasm⁸. The AMI induced by coronary vasospasm reverts back to normal with intravenous nitroglycerin which is shown by prompt relief of angina, normalization of ST segment elevation and normal cardiac enzymes. As in our case, the coronary vasospasm is coinciding with the onset of thyrotoxicosis. Thyrotoxicosis results from painless thyroiditis accounts up to 23% of all thyrotoxicosis cases. Patients suffering from thyroiditis in thyrotoxic phase have very similar clinical presentation to those with Grave's

disease, both having significant influence on the cardiovascular system. A recent study about a young patient without atherosclerotic coronary lesion and CAD risk factors having AMI due to thyrotoxicosis with painless thyroiditis has shown interesting findings⁹. Painless thyroiditis manifests as transient thyrotoxicosis followed by transient hypothyroidism or hyperthyroidism which was treated conservatively¹⁰. Our patient had no other conditions (e.g. connective tissue disorders, vasculitidisorders) that could precipitate an acute coronary event at such a young age. This is an interesting case report concerning a young person having an acute coronary event coinciding with the onset of thyrotoxicosis.

CONCLUSION

Thyrotoxicosis with painless thyroiditis induced acute myocardial infarction in a young man usually has normal coronary arteries without any coronary risk factors.

REFERENCE

1. Gowda RM, Khan IA, Soodini G, Vasavada BC, Sacchi TJ. Acute myocardial infarction with normal coronary arteries
2. Patanè S, Marte F, Patanè F, Di Bella G, Chiofalo S, Cinnirella G, et al. Acute myocardial infarction in a young patient with myocardial bridge and elevated levels of free triiodothyronine. *Int J Cardiol* 2009;132:140-2. associated with iatrogenic hyperthyroidism. *Int J Cardiol* 2003;90:327-
3. Klein I, Ojamaa K. Thyroid hormone and the cardiovascular system. *N Engl J Med* 2001;344:501-9.
4. Lee AY, Chang MC, Chen T, Shyu M, Chang C. Acute coronary syndrome and hyperthyroidism: two cases report. *Acta Cardiol Sin* 2003;19:201-4.
5. Kohno A, Hara Y. Severe myocardial ischemia following hormone replacement in two cases of hypothyroidism with normal coronary arteriogram. *Endocr J* 2001;48:565-72.
6. Kohno A, Hara Y. Severe myocardial ischemia following hormone replacement in two cases of hypothyroidism with normal coronary arteriogram. *Endocr J* 2001;48:565-72.
7. Masani ND, Northridge DB, Hall RJ. Severe coronary vasospasm associated with hyperthyroidism causing myocardial infarction. *Br Heart J* 1995;74:700-1.
8. Erem C, Ersoz HO, Karti SS, Ukiñç K, Hacıhasanoğlu A, Deger O, et al. Blood coagulation and fibrinolysis in patients with hyperthyroidism. *J Endocrinol Invest* 2002;25:345-50.
9. Hammond HK, White FC, Buxton IL, Saltzstein P, Brunton LL, Longhurst JC. Increased myocardial beta-receptors and adrenergic responses in hyperthyroid pigs. *Am J Physiol* 1987;252:283-90.
10. Kim HJ, Jung TS, Hahm JR, Hwang SJ, Lee SM, Jung JH, et al. Thyrotoxicosis-induced acute myocardial infarction due to painless thyroiditis. *Thyroid* 2011;21:1149-51.
11. Woolf PD, Daly R. Thyrotoxicosis with painless thyroiditis. *Am J Med* 1976;60:73-9.