

THE PRINCIPLES AND PRACTICE OF ECHOCARDIOGRAPHY

By

Hamid Ikram MD, FRCPE, FRACP, FRCP, FACC, FICA.

Head, Department of Cardiology,

The Princess Margaret Hospital, Christchurch, New Zealand.

INTRODUCTION

The development of echocardiography is probably the most important diagnostic advance in cardiology of this decade. Of the many techniques available it most closely approaches the ideal. It provides both qualitative and quantitative information regarding cardiac structure and function. Since ultra sound is non-invasive and at the energy levels used in diagnosis, entirely harmless, examinations may be performed without limitation.

The basis of echocardiography lies in the physical properties of ultra high frequency sound waves. These waves have a frequency of over 20 thousand cycles per second (Hetz). The frequencies used in medical diagnostic ultra sound are in the region of millions of cycles per second (Mega Herz). In these frequency ranges, ultra sound is inaudible and indeed behaves like light in that it is reflected from interfaces of tissues with varying acoustic densities.

The principal disadvantage of ultra sound is that it travels poorly in air. Hence the transducer must be in close contact with the patient's chest. An ultrasonic gel is routinely used to couple the transducer to the chest.

Transmission is similarly poor through air-filled lung and the ultrasonic beam gets to the heart through an area where the lung does not

cover the heart. This so-called 'echocardiographic window' is located close to the left side of the sternum from the 3rd to the 5th intercostal spaces. Its extent varies in individuals, being smaller in older patients and those with emphysema.

In most commercial echocardiographic ultrasound is produced by a barium titanate crystal which is struck electrically. The pulse of ultrasound lasts for about one microsecond. The rest of the time the echo transducer acts as a receiver for the reflected energy. Hence this particular method of using high frequency sound is known as pulsed-reflected ultrasound.

The reflected energy is then suitably amplified and recorded on polaroid film or a strip chart recorder. The latter although expensive, is the most informative means of recording the echo signals.

The Echocardiographic Examination

The examination is best performed with the patient lying in the semi-left lateral position. The examiner may use his left hand for manipulation of the transducer and use the right hand for adjusting the controls. Although this was traditional the right is frequently used to hold the transducer.

To carry out a complete echo examination the problem must be defined at the start. For

example it is pointless spending a long time trying to record the pulmonary valve if the clinical problem is a pericardial effusion. Usually the complete examination involves recording of all the cardiac valves and the left ventricle.

To accomplish this the echo beam is directed along 4 standard directions (Fig. 1). The first is upwards and medially through the walls of the aorta, the aortic valve and the left atrium. The second is through the anterior leaflet of the mitral valve and the left atrium; the third is through the anterior and posterior leaflets of the mitral valve and the fourth view is through the interventricular septum and posterior wall of the left ventricle. This view is used for assessment of left ventricular size and ejection fraction.

If access to the heart through the echo window is not possible, the examination may be performed from the subxiphoid or supra sternal approaches. The mitral valve or aortic root are located first as they produce the most distinctive echos. The other structures are then recorded.

Interpretation

The information obtainable from echo examination is so vast that it is not possible to give a detailed account in a short article. It is only possible to provide a few examples. The commonest application of this technique is for the diagnosis of valvular heart disease, pericardial effusions, intracardiac tumours and left ventricular function.

The normal mitral valve is shown in Fig. 2. The diagnosis of mitral stenosis was one of the earliest uses of this technique. The rate of diastolic closure of the mitral valve—so-called EF slope of the anterior leaflet, was the index most frequently used (Fig. 3). This has been

shown to correlate well with mitral valve areas measured by catheterization. The quality of the mitral valve i.e., whether it is fibrosed, rigid or calcified, and hence its suitability for closed valvotomy, can also be assessed.

Mitral incompetence from rheumatic fever cannot be diagnosed directly. It can be assessed indirectly by changes in left atrial and left ventricular dimensions and function.

Mitral incompetence due to prolapse of the mitral valve (Fig. 4) and torn chordae tendineae can be diagnosed directly.

Aortic stenosis is detectable by recording of the aortic valve cusps. The normal opening of the 'box' (Fig. 5) is reduced in aortic stenosis (Fig. 6). Unfortunately stenotic valves are invariably calcified and details of cusp motion are unrecordable in the majority of patients. The presence of valve calcification however, has considerable diagnostic value and minor degrees are more reliably detectable by ultrasound than by radiographic methods. The gradient across the aortic valve can be measured by using the left ventricular dimension and thickness to estimate left ventricular pressure from the La Place relationship (Bennett and Evans, 1975). If arterial blood pressure (by sphygmomanometer cuff) is measured at the same time, then the peak systolic gradient can be obtained. This is remarkably close to the gradient obtained at catheterization.

Aortic incompetence is also not susceptible to direct assessment. The regurgitant stream vibrates the mitral valve causing high frequency oscillations of the mitral cusps (Fig. 7). This is the echo equivalent of the Austin Flint murmur of aortic incompetence and is a useful diagnostic sign of aortic incompetence but no

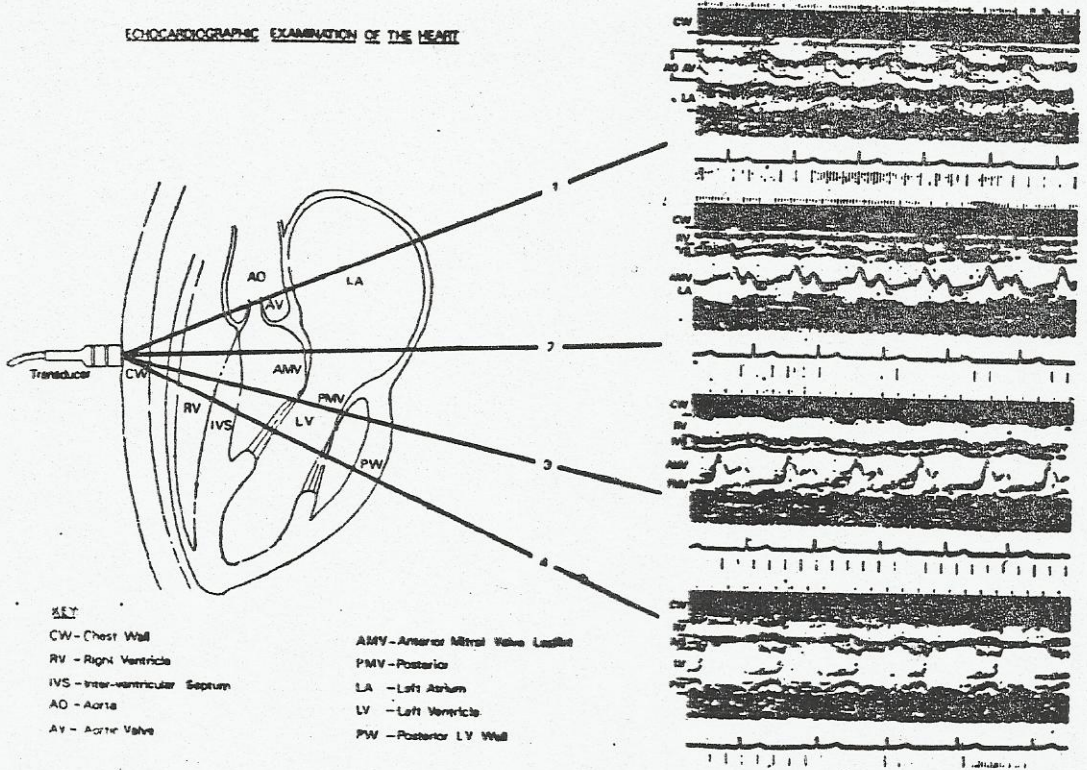


Fig. 1—The 4 standard beam directions.

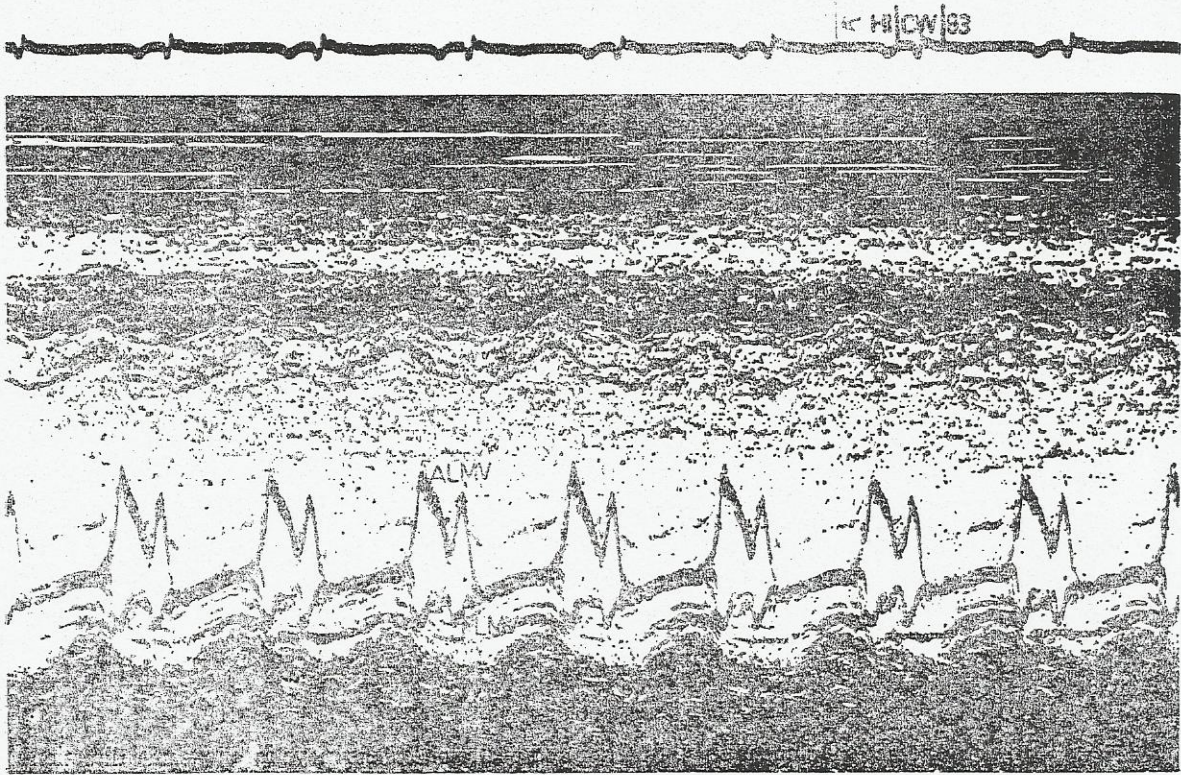


Fig. 2—The normal mitral valve. ALMV=Anterior leaflet of mitral valve. PLMV=Posterior leaflet of mitral valve.

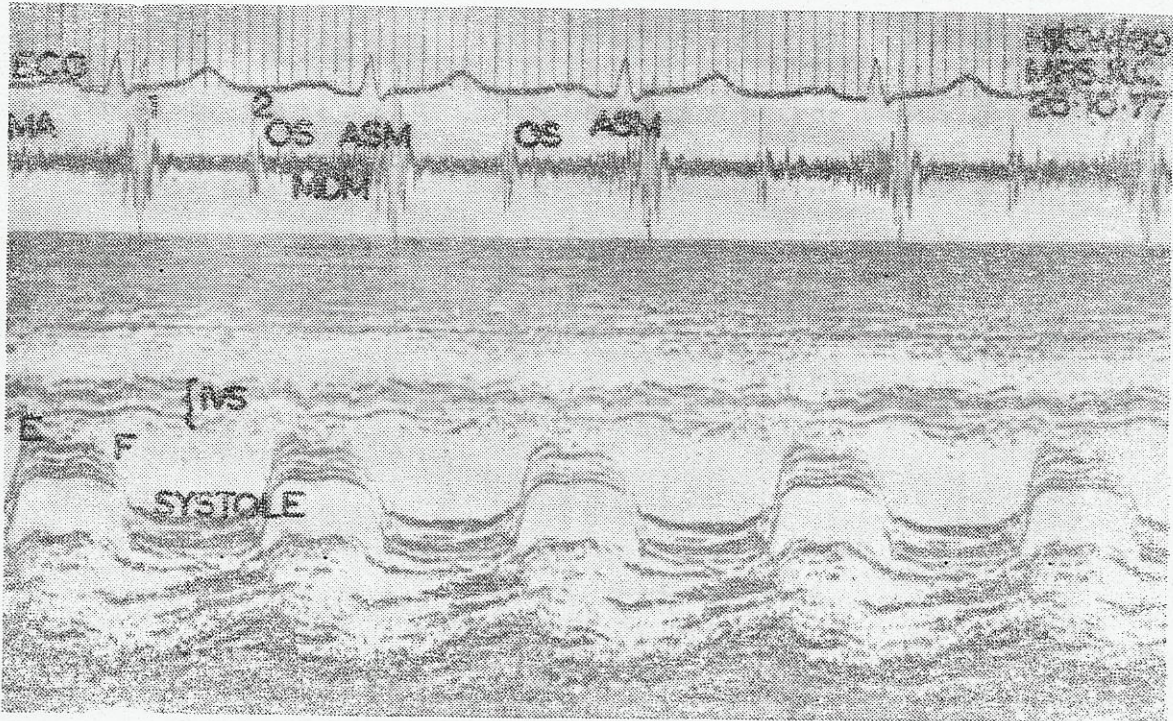


Fig:—3 Mitral Stenosis: EF slope is slow. Anterior and posterior leaflets move in the same direction in diastole. The valve cusps have multiple echos indicating fibrotic thickening.

estimate of its severity. In acute aortic incompetence the very high left ventricular end-diastolic pressure causes the mitral valve to close before systole has occurred. This pre-closure of the mitral valve usually denotes severe and acute aortic incompetence.

It is difficult to record the entire tricuspid valve, but usually possible to obtain the anterior cusp. This shows the same M-shaped motion as the mitral valve. Tricuspid stenosis also causes decrease in the EF slope and tricuspid calcification can be detected. Tricuspid incompetence is not usually directly diagnosable except for the rare case of tricuspid prolapse.

The pulmonary valve is the most difficult valve to record, although with experience it can be examined in 80% of cases. Because of its position, only the posterior cusp is accessible to examination.

Pulmonary stenosis causes an increase in the 'A' wave of the pulmonary valve tracing while pulmonary hypertension causes a decrease of this wave. Other diagnostic applications have been described but as yet are not firmly established.

One of the earliest uses of echocardiography was for the diagnosis of intracardiac masses and it still remains the best method for their detection. Solid lesions in the right and left side of the heart (Fig. 8) have now been reported. They include a variety of pathological entities including blood clots.

Among the first uses of echocardiography was the detection of pericardial fluid (Fig. 9). This is still a major application of the technique. Unfortunately it is not as reliable in the detection of pericardial thickening and calcification.

Echocardiography permits measurement of alterations in left ventricular dimension and function. Hence severe dilatation as happens in congestive cardiomyopathy and hypertrophy as in Hypertrophic cardiomyopathy (Fig. 10) can be detected with much greater precision than with any other technique. Similar changes due to, for example cardiac failure or hypertension, may also be detected.

Left ventricular functional abnormalities can be readily detected by echocardiography. A variety of indices have been described such as ejection fraction, mean VCF etc. These are all based on the extent and rate of shortening of the echo dimension between the left side of the septum and the endocardial surface of the left ventricle. The percentage shortening of this dimension alone is as useful as the derived indices.

It is impossible to convey in a short article such as this the tremendous impact of echocardiography on cardiological diagnoses. Large areas have not been touched. These include the important and complex area of congenital heart disease, the use of ultrasonic contrast medium to produce contrast echograms and two-dimensional real time echograms.

Apart from diagnostic information, echocardiography has provided a unique means of studying cardiac function. The uniqueness lies in its non-invasiveness. Thus it is possible to study cardiac function without the complicating influence of pain, intracardiac instruments and toxic contrast media. The technique is destined to continue its already impressive growth for a long time to come.

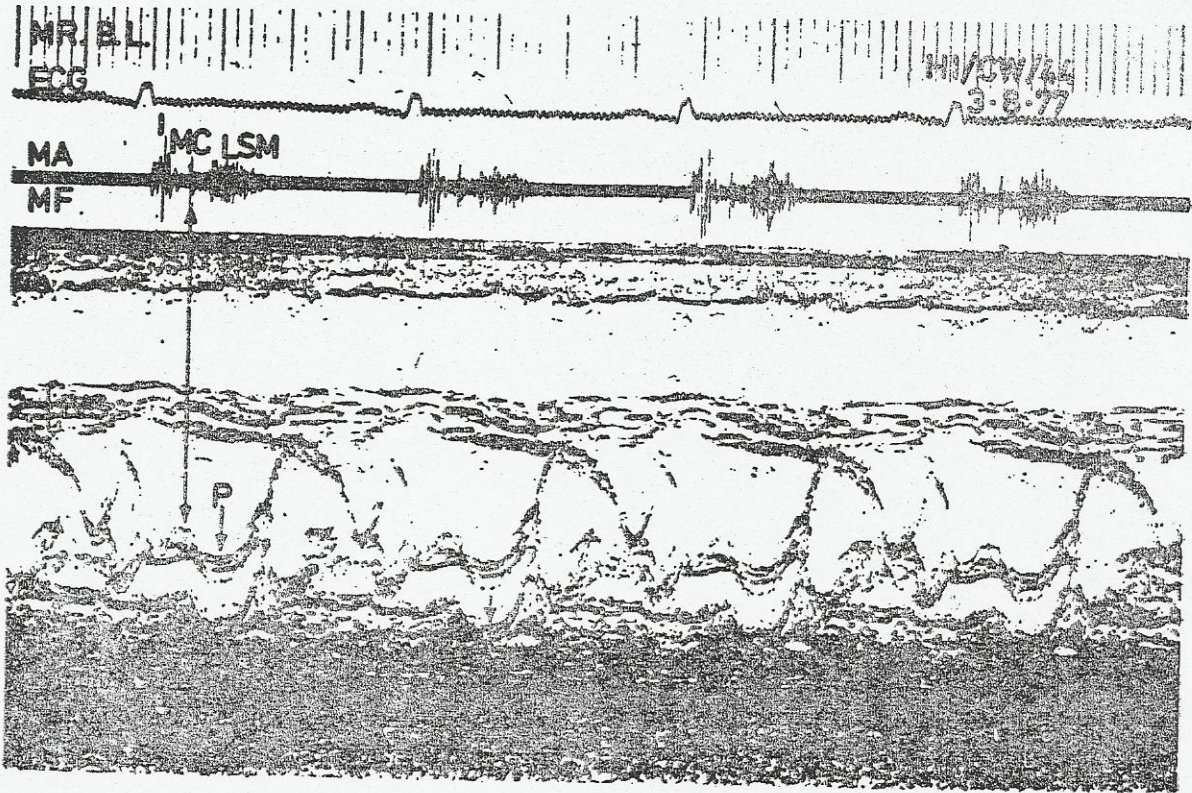


Fig:—4 Late systolic mitral valve prolapse (so called click-murmur syndrome). P=systolic prolapse. MC=mid systolic click, LSM=late systolic murmur.

MRS J.J. 13-4-79

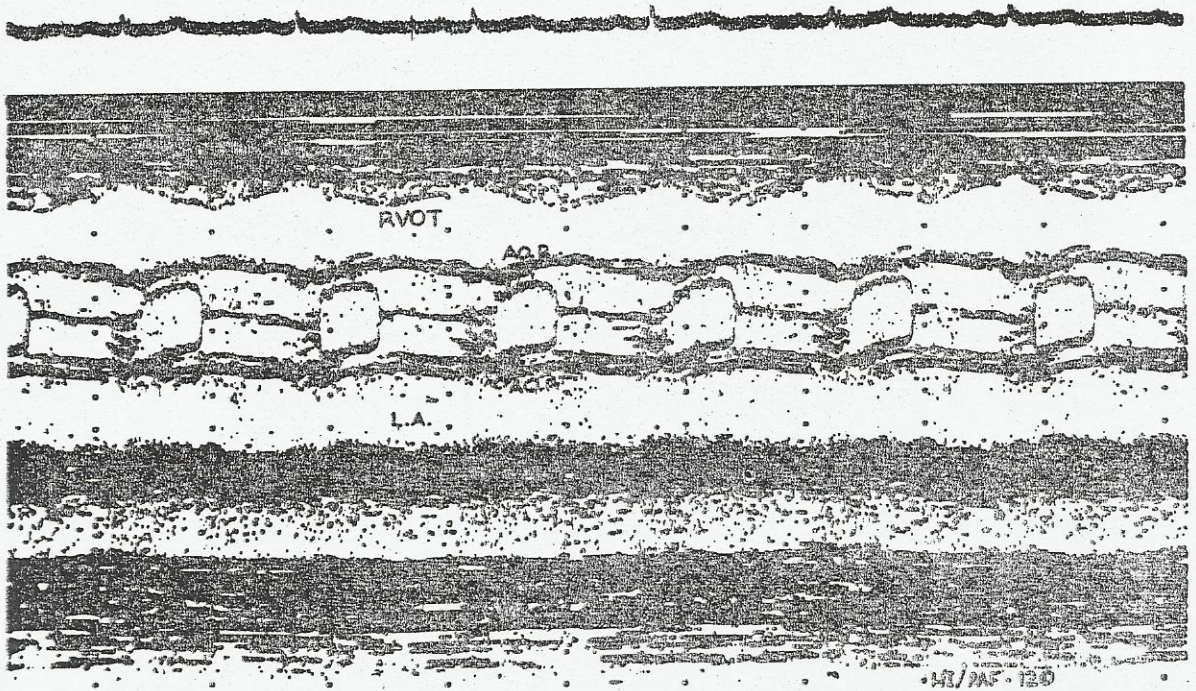
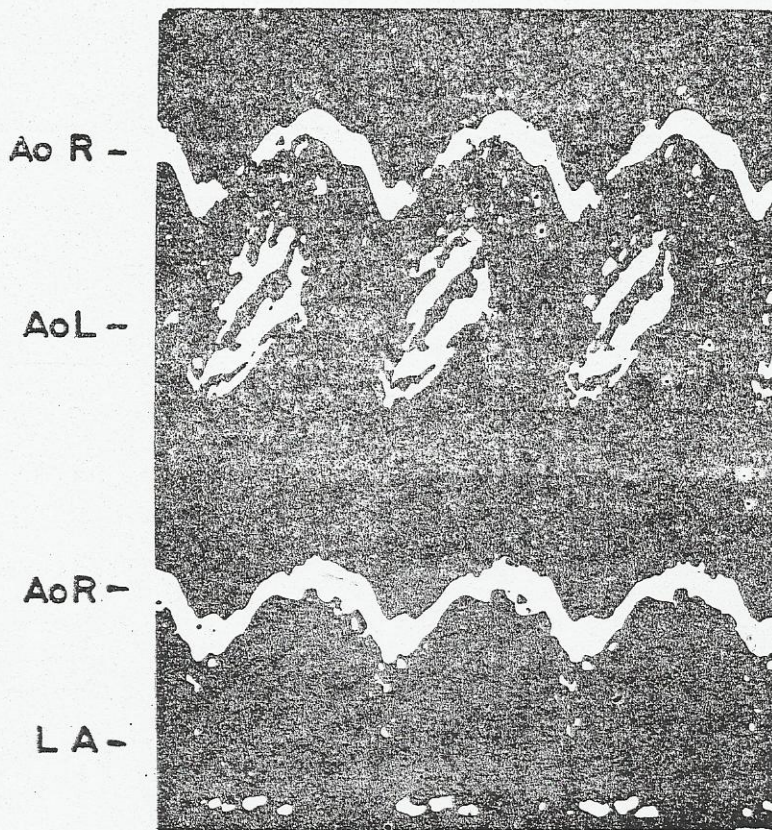


Fig: 5—Normal aortic valve showing box-like configuration in systole.



SEVERE AORTIC STENOSIS

Fig: 6—Severe Aortic Stenosis AoR=Aortic root AoL=Aortic leaflets fused to form slit-like orifice.

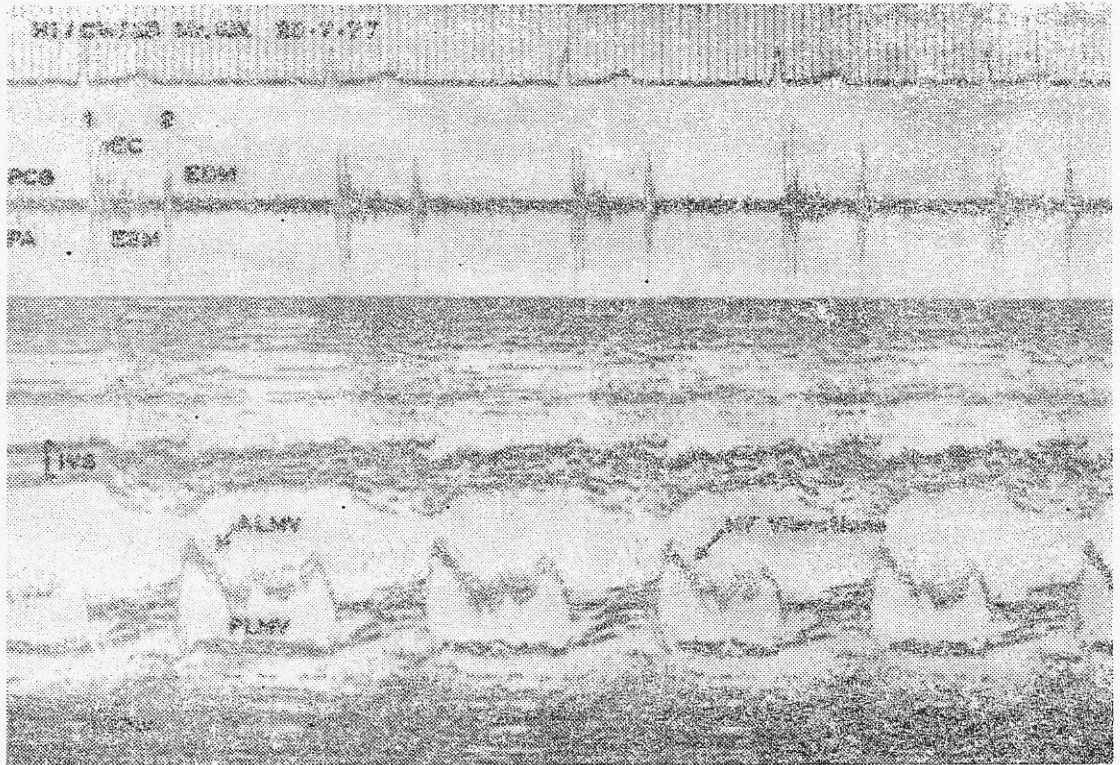


Fig. 7—Mitral valve in aortic incompetence showing high frequency vibrations (HF).

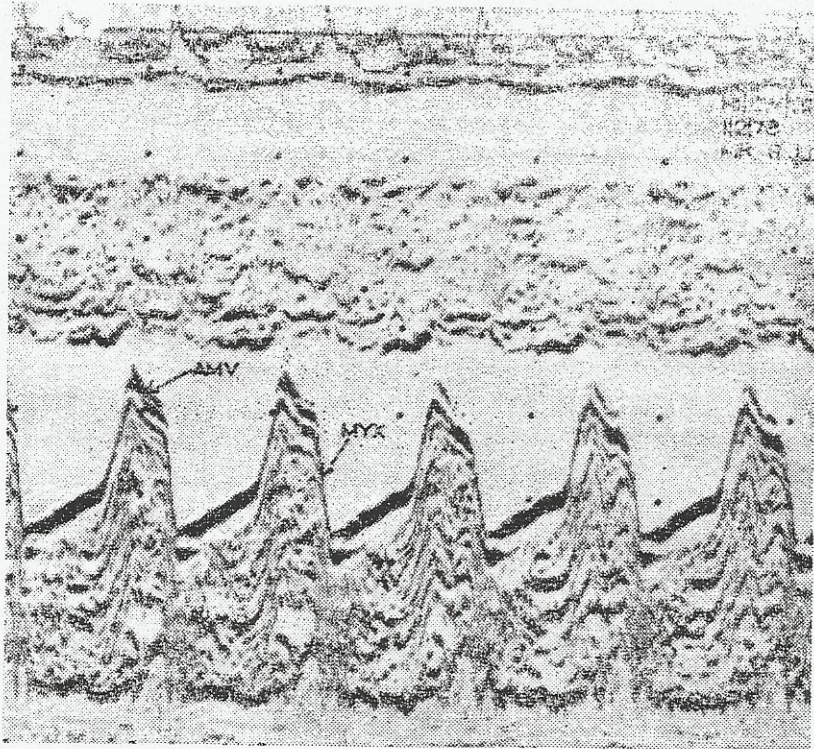


Fig: 8—Left Atrial Myxoma AMV=Anterior leaflet of mitral valve., MYX=Myxoma mass.

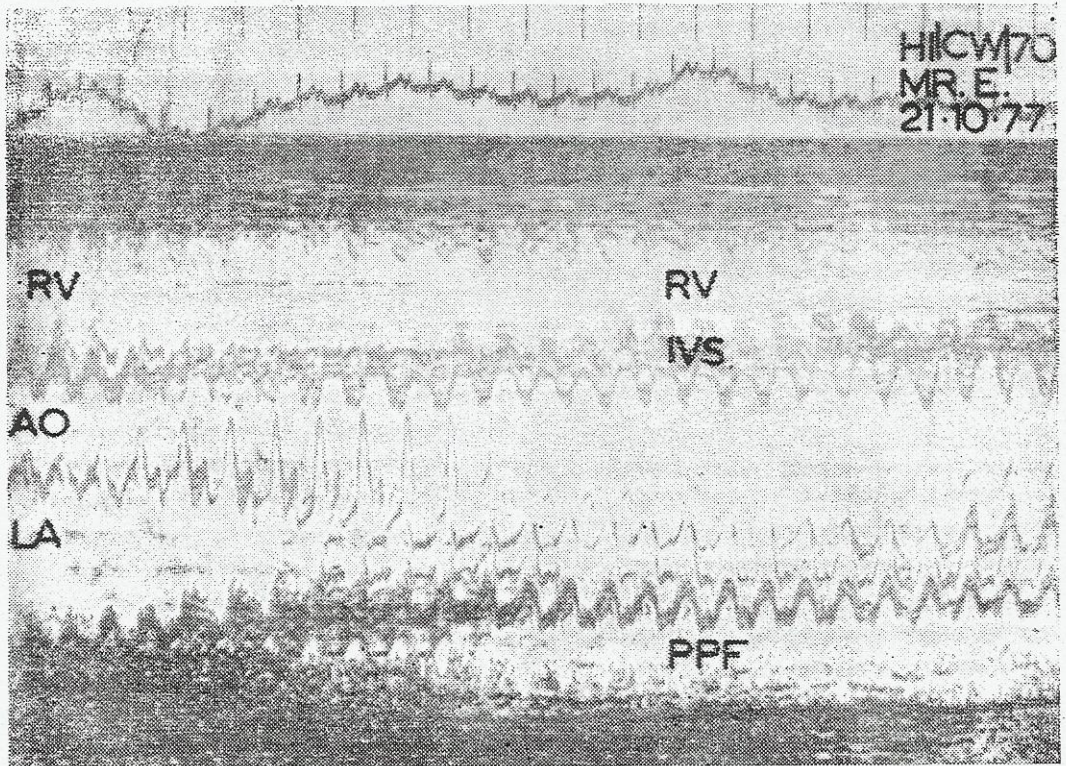


Fig: 9—Scan from aorta to left ventricle showing pericardial fluid (PPF) posterior to the ventricle.

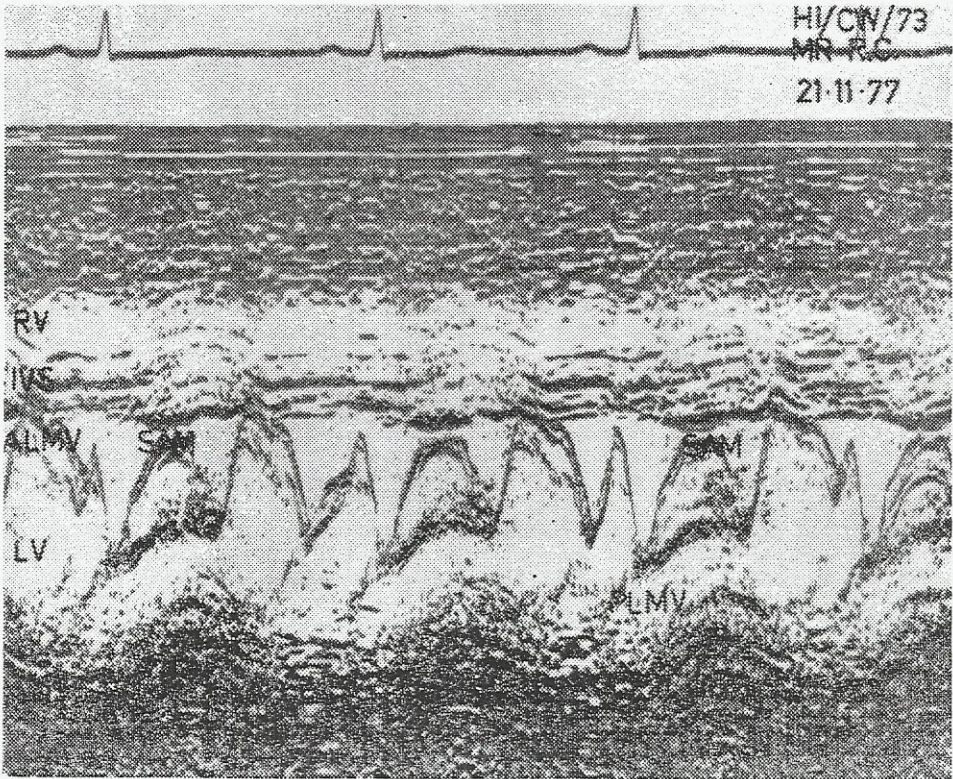


Fig. 10—Hypertrophic obstructive cardiomyopathy showing abnormal systolic anterior motion (SAM) of the mitral valve.

References

1. Echocardiography by Feigenbaum H. Lea and Febiger. Philadelphia, 1976.
2. Bennett, D.H., Evans, D.W. and Raj, M.V.J. Echocardiographic left ventricular dimensions in pressure and volume overload. Their use in assessing aortic stenosis. *British Heart Journal* 37:971-977, 1977.

—:0:—

NEXT ISSUE
OF
Pakistan Heart Journal
WILL HAVE ABSTRACTS AND
SPECIAL ARTICLES SUBMITTED
FOR
IV ALL PAKISTAN CONGRESS OF
CARDIOLOGY, DEC. 3-4, 1979
AT N.I.C.V.D., KARACHI.