

FIRST YEAR OF ECHOCARDIOGRAPHY IN PAKISTAN

by

Dr. Azhar M.A. Faruqui, FRCP, FACC*, and
Dr. Ismail S. Ahmad, MB.,B.S.**

Echocardiography, a well established non-invasive cardiac diagnostic modality has been available in Karachi since about one year. This presentation will attempt to give a brief introduction to the technique and an analysis of the local experience in the usefulness of the technique.

Technique

Echocardiography is performed with the patient lying supine or in the left lateral position with the head elevated slightly. A transducer which both sends ultrasound waves into the body and receives the returning echos is placed in the 3rd or 4th left interspace just lateral to the sternum. The transducer is connected by wire to the main module which displays the returning signal on a small CRT (T.V. screen). The output can also be recorded on Polaroid film or on photographic paper. Echos (Fig. 1) are reflected from the various interfaces inside the heart (e.g. endocardium and blood or myocardium and pericardium having different acoustic conduction produce an interface and reflect back echos). These echos are then portrayed as parallel lines that move in different directions depending on the cardiac cycle events (Fig. 2). As such the accurate dimensions, both internal and external of various chambers, thickness of left ventricular walls and the motion of all these structures can be accurately recorded and studied in detail not permitted by any other means.

Local Experience

So far a total of 148 cases have been studied by Echo. This total combines patients referred to the author's personal facility since May 1978 and those studied by the author at the National Institute of Cardiovascular Diseases' facility since January 1979. *The breakdown of the various disease categories does not in any way represent the prevalence of diseases as they exist in our society.* It only shows the pattern of diseases that were referred for diagnosis by Echo.

Echo-Cardiographic Diagnosis Made:

1. *Valvular Heart Disease (Total 61 cases)*
 - (a) Prolapsing Mitral Valve. 54%
 - (b) Rheumatic Heart Disease 38%
 - (c) Bacterial Endocarditis 2%
 - (d) Other causes. 6%
2. *Cardiomyopathies (total 25 cases)*
 - (a) Congestive 82%
 - (b) Hypertrophic 18%
3. *Pericardial Diseases (Total 11 cases)*
 - (a) Effusion alone 73%
 - (b) Constriction 27%(With or without effusion)
4. *Congenital Heart Diseases (Total 22 cases)*
5. *Ischemic Heart Disease (Total 10 cases)*
 - (a) With evidence of L.V. Aneurysm 30%

* Physician, National Institute of Cardiovascular Diseases (Pakistan), Karachi.

** R.M.O., National Institute of Cardiovascular Diseases, (Pakistan), Karachi.

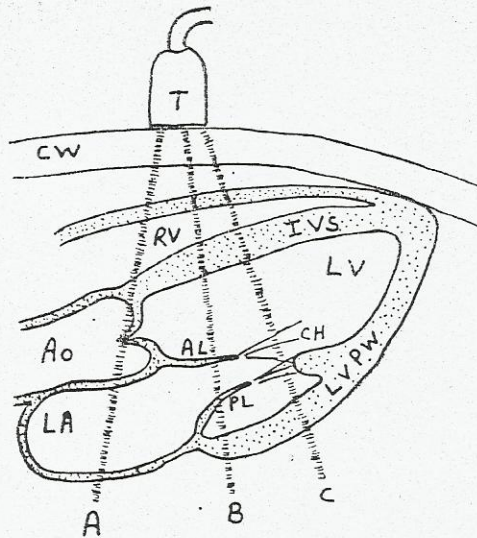


Fig. 1. Diagrammatic view of a long axis cross-section of the heart. Echo beam from the transducer on the chest can be angled at various structures as in positions A or B or C T-Transducer; CW-chest wall; RV-right ventricle; IVS-interventricular septum; AO-aorta; LV-left ventricle; AL-anterior leaflet of the mitral valve; PL-posterior leaflet of the mitral valve; LVPW-left ventricular posterior wall; LA-left atrium; CH-chordae.

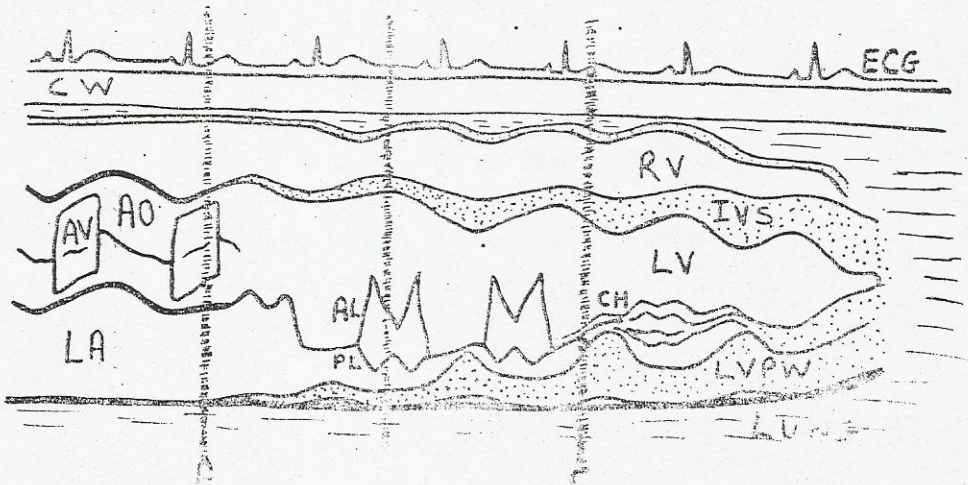


Fig. 2. Tracing of an actual Echo recording showing a sweep from the aorta to the apex. Lines A, B & C are in the same locations as in Fig. 1. Except for cyclical motion of the various structures, the sweep very much looks like the cross section of the heart in Fig. 1. All abbreviations are the same as in Fig. 1. AV-open aortic leaflets forming a box

6. *Accuracy (Total 34 cases)*

Comparison of Echo with Surgery Correlation:

- (A) Clinical Diagnosis confirmed by Echo (56 cases) 44%
 - (B) Clinical Diagnosis in Error or Incomplete (74 cases) 51%
 - (C) Pre-clinical Diagnosis made before Echo (3 cases) 5%
- Comparison of Echo Diagnosis by Catheterization or Surgery: 24 cases
- (A) Catheterization and Echo differ on Diagnosis - 2 cases.
 - (1) At Surgery Echo proven correct - 1 cases
 - (2) Patient awaiting surgery - 1 cases

Discussion

As a result of our study on data the main conclusion was that Echo-cardiography has been as satisfying as in the Western Countries. Review of our data revealed differences in criteria for various disease states between Western and our patients, i. being presentingly under-recognized and could be diagnosed upon. Also, a comparison of the usual control Echo parameters found for were

There are two things worth noting from our local experience. Firstly, that the clinical diagnosis turned out to be in error in 51% of the cases and the clinical diagnosis could be made in 5% of cases only to preferal. Thus 56% of them probably would have received in appropriate treatment if they had not had an Echo performed or in the absence of Echo, Cardiac Catheterization and angiography performed. This experience

is not significantly different from what has already been noted in the West. Secondly, Mitral valve prolapse has turned out to be a very frequent Echo diagnosis in cases which were referred with systolic murmurs with or without systolic clicks. These patients, mostly females with minor E.C.G. changes and atypical chest pain had mostly been mis labelled as rheumatic heart disease patients. Against, this experience parallels what was seen in the Western Countries as an explosion in the diagnosis of mitral valve prolapse after introduction of Echo.

For the guidance of our practitioners and to place Echo-Cardiography in its proper perspective Vis a vis Cardiac Catheterization and angiography the following tabulation is presented:

A. A FEW DIAGNOSIS WHICH BE CAN MADE WITH GREATER CERTAINTY THAN AT CARDIAC CATHETERIZATION OR ANGIOGRAPHY

1. Mitral stenosis and state of mitral valve leaflets and aortic valve (Talo) mitral leaflets.
2. Atrial myxoma or other tumors.
3. Mitral valve prolapse and mitral regurgitation, valvular atresia.
4. I.H.S.S. (Hypertrophic obstructive cardiomyopathy).
5. Pericardial effusion.
6. Left and right ventricular and Aortic wall thickness
7. Timing of murmurs, sounds or abnormal pulsations with intracardiac events.
8. Systolic time intervals.

B. A FEW DIAGNOSIS WHICH CAN BE MADE WITH EQUAL OR ONLY SLIGHTLY LESS CERTAINTY THAN AT CARDIAC CATHETERIZATION AND ANGIOGRAPHY

1. Aortic regurgitation.
2. Volume overload of the right ventricle (ASD, TI, PI)
3. Presence of pulmonary hypertension.
4. Left ventricular function in diseases affecting the left ventricle symmetrically (End diastolic volume, stroke volume, cardiac output, ejection fraction, mean velocity of circumferential fibre shortening).
5. Strategically located left ventricular aneurysms.
6. Presence of endocarditis vegetations on cardiac valves.
7. Tricuspid stenosis and tricuspid regurgitation.
8. Strategically located aortic wall dissecting aneurysms.
9. Aortic dilatation. Sinus valvula aneurysm.
10. Calcific Aortic stenosis.
11. A-V cushion defects and presence or absence of single A-V valve.
12. Ebstein's anomaly. Hypoplastic left ventricle.
13. Classification of W.P.W. syndrome by wall motion and study of other arrhythmias conduction defects.
14. Congestive cardiomyopathy. Endocardial fibroelastosis.
15. False aneurysm of the left ventricle.
16. Prosthetic valve functioning.

C. A FEW CONDITIONS WHERE ECHO IS USEFUL BUT DIAGNOSIS MADE WITH LESS CERTAINTY THAN CARDIAC CATHETERIZATION AND ANGIOGRAPHY

1. Pulmonic valve stenosis.
2. Aortic leaflet prolapse. Flail aortic leaflet.
3. Constrictive pericarditis. Absent pericardium.
4. Single ventricle.
5. Total anomalous venous return.
6. Cor-triatriatum.
7. Transposition of the great vessels.
8. Tetralogy of Fallot.
9. Double outlet right ventricle.
10. Truncus arteriosus.
11. Degree of volume overload as in P.D.A. or other A-V shunts.

D. ADVANTAGES OF ECHOCARDIOGRAPHY OVER CARDIAC CATHETERIZATION AND ANGIOGRAPHY

1. No known contra-indications or side effects.
2. Painless and non-invasive.
3. Repeated and frequent follow-up examinations can be performed to follow the natural history of the diseases and/or the effect of treatment.
4. Important in decision making as to timing of cardiac catheterization and/or cardiac surgery and helping decide type of surgery (e.g., mitral commissurotomy VS. valve replacement).

5. Superior diagnostic capability in mitral valve prolapse. I.H.S.S. left atrial myxoma and pericardial effusion, etc.
6. Cheaper than cardiac catheterization and angiography.
7. Can be performed at patient's bedside.

E. *LIMITATIONS OF ECHOCARDIOGRAPHY*

1. 5-10% of patients are not suitable candidates for Echo due to severe emphysema or chest wall abnormalities.
2. Diseases affecting the cardiac chambers asymmetrically are more difficult to diagnose and there may be false negatives reported.

3. Limitations and proven usefulness of Echo must be realized otherwise over-interpretation by inadequately trained persons may be potentially dangerous and misleading.

RECOMMENDED READING TEXTS

1. Echocardiography by Harvey Feigenbaum. 2nd Edition 1976. Lea and Febiger.
2. Echocardiography: A Teaching Atlas. by J.M. Felner and R.C. Schlant 1976. Gurne and Stratton.
3. The Heart by J.W. Hurst et al. (Ed.) Chapter on Echocardiography 4th Edition 1978. Mcgraw Hill Company.