

# Real Time Two Dimensional Echocardiography In The Diagnosis Of Left Atrial Myxoma

By

\*SUSIL C. MUNSI, DM (Card), FRCP, FACC, FICA \*\*SATYAVAN SHARMA, MD (Med.), DM (Card.), MNAMS, FICA \*\*\*ASHOK BHUPALI, MD (Med.), DM (Card.)  
\*\*\*M.G. PILLAI, MD (Med.), DM (Card.) \*\*\*\*S.S. BHATTACHARYA, MS (Surg.), M.Ch. (Cardiac surgery).

## INTRODUCTION

Echocardiography (1-8) is an established screening procedure in cases of suspected left atrial myxoma. Generally M mode echocardiography is adequate either to confirm or to rule out the presence of an atrial myxoma though falsely negative or atypical (9-12-15) findings have been reported with M mode study.

2 D echo has been used (13-16) to diagnose left atrial myxoma and has distinct advantages over M mode echocardiography as well as other investigative techniques.

## CASE REPORT

A 35 year old woman was referred for cardiac surgery for suspected mitral stenosis. For two years, she had dyspnea on moderate exertion and regular palpitations. There was no postural relationship of symptoms. She denied any history of past rheumatic fever, embolisation or constitutional symptoms. On physical examination, she was in sinus rhythm and the

findings were indistinguishable from mitral stenosis. The electrocardiogram was normal except for left atrial enlargement. Chest X-ray PA view demonstrated prominence of upper lobe veins, mild cardiomegaly, left atrial enlargement and prominent main pulmonary artery.

M-mode echocardiography was performed using commercially available Unirad Sonograph equipment. The recordings were made on a Honeywell strip chart recorder using a 2.25 MHz non focused type of transducer. Multiple linear moving echoes were seen behind the mitral valve and within the left atrial cavity consistent with an atrial myxoma. E-F slope of the mitral valve was reduced, and the 'A' wave was absent. A 2 D echo using a commercially available ATL mark III real time system with 720 A scan head showed a large rounded tumour occupying the entire left atrial cavity. In the mitral long axis view, the tumour mass was seen behind the mitral valve in systole (Fig.1) and moved into mitral orifice during diastole (Fig.1), the attachment

---

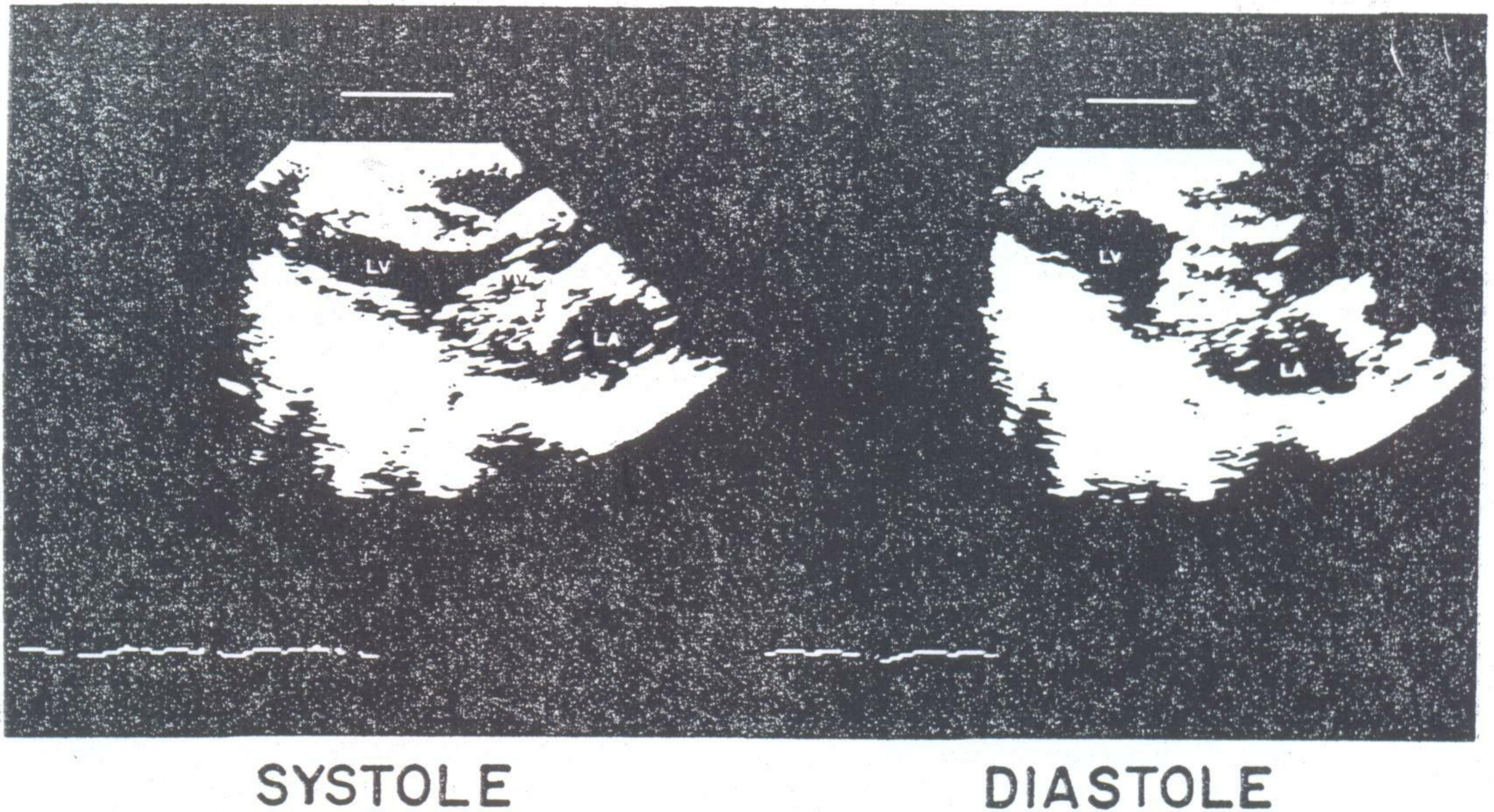
\*Honorary Assistant Professor

\*\*Lecturer

\*\*\*Registrar

\*\*\*\*Assistant Professor.

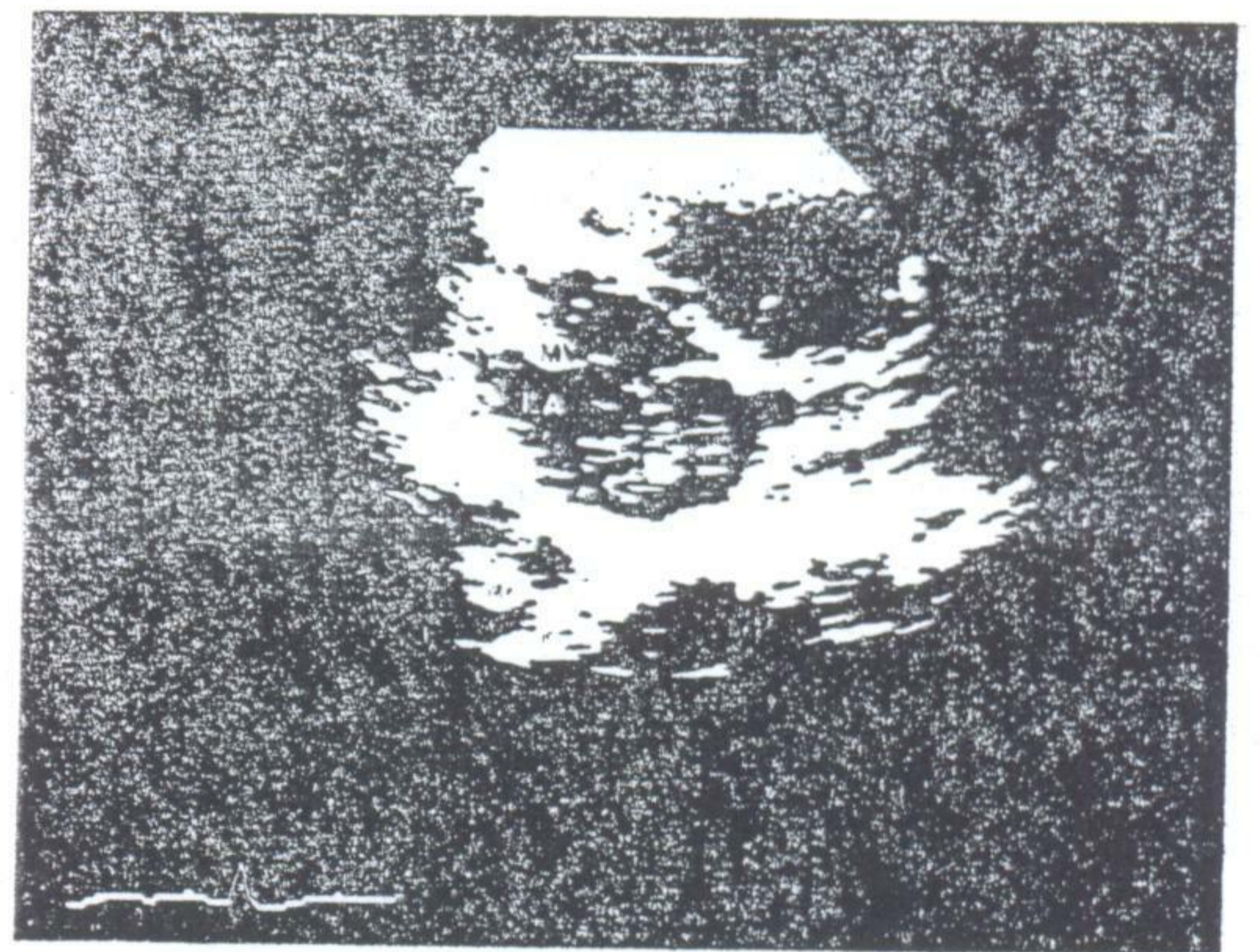
Department of Cardiology, K.E.M. Hospital, Parel, Bombay — 400 012, India.



*Fig. 1.* 2 D Sector Scan in mitral long axis view shows tumor mass (T) in left atrium (LA) in systole and prolapsing into left ventricle (LV) in diastole.

MV: Mitral valve

of the tumour could not be delineated, but the free motion of the tumour suggested a long stalk. The mitral orifice was large and circular in short axis cross sectional view and appeared to be completely filled with tumour echoes in diastole. The mitral leaflets were thin and free of any disease process. An apical four chambered view showed a tumour in the left atrial cavity (Fig.2). During diastole, a large segment of tumour prolapses into the left ventricular cavity. No mass in right atrium or in ventricles thus excluding the possibility of multiple tumours. Multiple translucent areas suggesting haemorrhage in the tumor were detected in mitral long axis and apical four chambered view. At surgery a 9 to 10 cm. diameter myxoma with a broad stalk involving 4-6 sq cm of atrial septum was removed. The



*Fig. 2.* 2 D echogram in apical four chambered view demonstrating tumour (T) in left atrium. Multiple translucent areas suggest haemorrhage in the tumour (T).

atrial septum was repaired with the use of prosthetic dacron material. The tumor was of firm consistency and contained no areas of calcification. However, there were patchy areas of haemorrhage seen in the tumor. Histology confirmed the diagnosis of myxoma. The patient recovered from the surgery uneventfully and became asymptomatic. The repeat M-mode and 2 D echo studies revealed no evidence of the tumour (Fig.3).

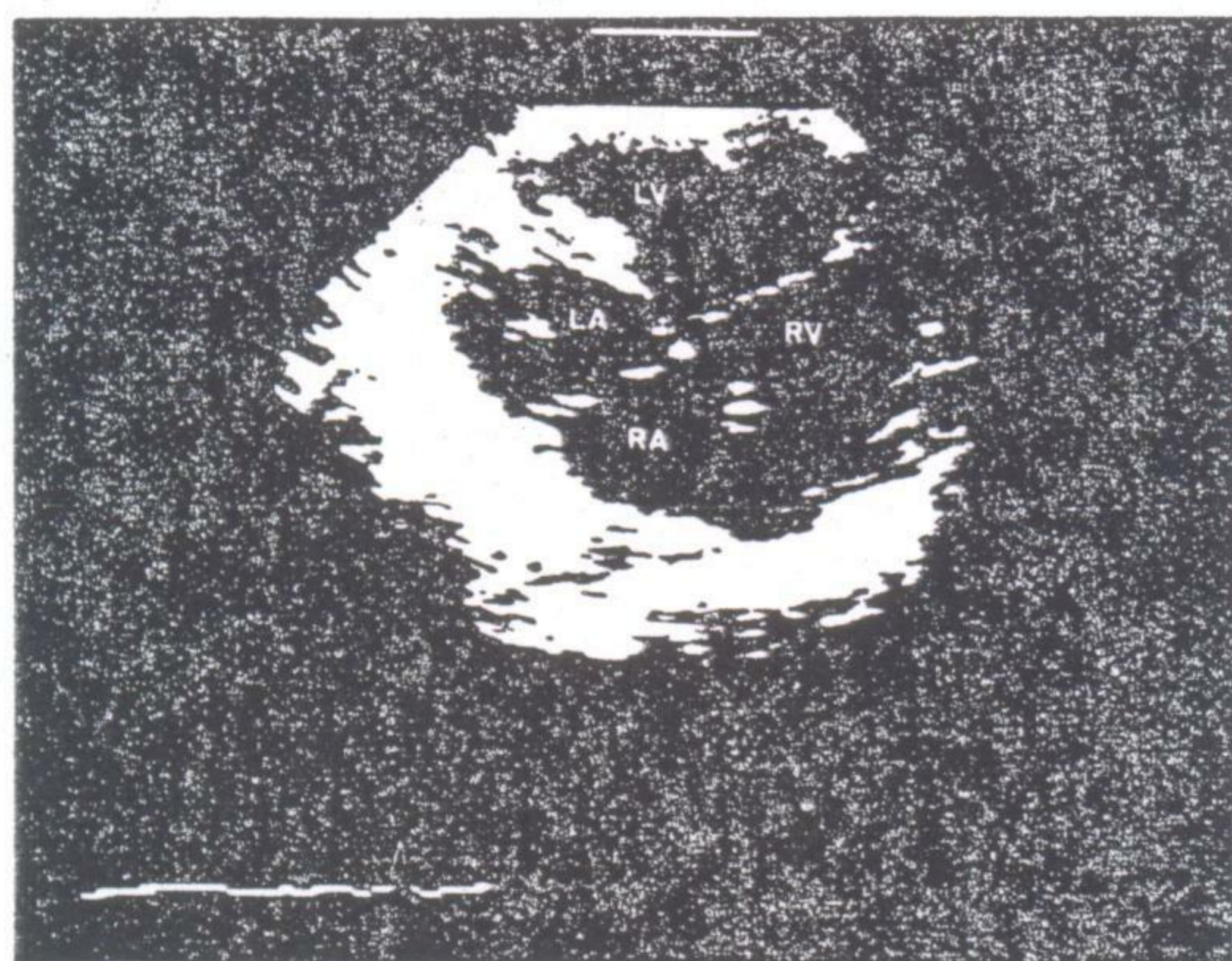


Fig. 3. 2 D echogram apical four chambered view (post operative) shows left atrial (LA) cavity free of tumor mass, right atrium (RA) ventricle (RV) and left ventricle (LV) too are free of any mass.

### DISCUSSION.

Because of the infrequent occurrence and the nonspecific signs and symptoms, the clinical diagnosis of atrial myxomas was rare prior to the advent of echocardiography (17-18). Echocardiography has changed the status of these tumours from unsuspected surgical surprise or pathological findings to readily diagnosed entities. During last 5 years, we diagnosed seven cases of left atrial myxoma by echocardiography and four of them

have been reported elsewhere(6). Against this only in 2 cases antemortem diagnosis was made in a twelve year period prior to echocardiography(19).

Since the first published case by Effert and Domanig(1) the M-mode echocardiographic features, diagnostic of left atrial myxoma, have been well documented (2-8). The definitive diagnosis requires the demonstration of abnormal echoes in the left atrium since multiple echoes in the region of mitral valve alone can be caused by vegetations (20), prolapsed mitral valve (8), calcified valve (8) or flail mitral leaflet (16). Occasionally, even false positive or false negative diagnosis can be entertained by M-mode technique. Nonvisualization of myxoma in the left atrial cavity (false negative) have been reported (8-11-12-15). In two instances(8-11), the authors attributed this to the tumour having the same density as blood, whereas in other two cases (12-15), calcification of the leading edge of the tumor caused acoustic shadowing and led to erroneous interpretation. A calcified mobile blood clot in the left atrium (ball valve thrombus) may be indistinguishable from myxoma (8) and rarely the multiple echoes in left atrium may represent reverberation echoes rather than tumor echoes (false positive) (16).

Though M-mode echocardiographic features are characteristic, the two dimensional echo studies have certain advantages and have been used in the diagnosis of left atrial myxoma (13-16). In real time 2D technique it is easy to demonstrate the tumor and delineate its shape, size, mobility and other characteristics. 2 D echo can demonstrate areas of strong echo reflection which indicate tumor calcification (16). Multiple echolucent areas can be detected within the tumor and these may represent areas of haemorrhage(21). In addition 2 D echo overcomes the technical

problems of false positive or false negative echo in M-mode recordings.

In our case a large mass completely filling the left atrial cavity during systole and prolapsing into the mitral orifice during diastole was demonstrated by real time imaging. At surgery large tumor (myxoma) was detected which was not calcified but had areas of patchy haemorrhage. On 2 D echocardiography multiple translucent areas were seen suggestive haemorrhage in the tumor and these findings were confirmed at surgery.

2 D echocardiography should be performed in mitral long axis, short axis and apical four chamber views. The long axis sector of the mitral valve is particularly useful to visualise the abnormal echoes in the left atrial cavity and to observe the extension behind the mitral valve. Both short axis and long axis view of mitral valve are necessary to assess the valve mobility and anatomy. Conditions like valve calcification, flail leaflets or prolapse mitral leaflets which on M-mode echocardiography may produce multiple echoes in region of the mitral valve can easily be excluded by visualising the mitral valve on 2 D scan. It is well known that atrial myxomas can be multiple. Hence, the apical four chambered view will help to detect or exclude any mass in other cardiac chambers.

In conclusion, the 2 D echocardiographic technique provides detailed information and is at present the best technique to diagnose cardiac tumours.

### SUMMARY

A case of left atrial myxoma diagnosed by M-mode echocardiography and subsequently

confirmed by Real time 2 D technique is presented. The noninvasive 2 D echo provides detailed diagnostic information which outweighs other available diagnostic techniques. Two dimensional echocardiography at present is the best procedure for diagnosing cardiac tumours.

### REFERENCES

1. Effert S, Domanig E: The diagnosis of intra-atrial tumors and thrombi by the ultrasonic echo method. *German Med. Monthly*, 4: 1-3, 1959 (Quoted by 8).
2. Martinez, EC, Giles TD, Burch GE: Echocardiographic diagnosis of left atrial myxoma. *Amer.J. Cardiol.* 33: 281-285, 1974.
3. Bass NM, Sharrat GP: Left atrial myxoma diagnosed by echocardiography, with observations of tumor movement. *Brit. Heart J.* 35: 1332-1335, 1973.
4. Popp RL, Harrison DC: Ultrasound for the diagnosis of atrial tumors. *Ann.Int. Med.* 71:785-787, 1969.
5. Srivastava TN, Fletcher E: The echocardiogram in left atrial myxoma. *Amer. J. Med.* 54: 136-139, 1973.
6. Dalal JJ, Vengsarkar AS, Kinare SG, Nair KG: Echocardiographic study of left atrial myxoma. *J. Postgrad. Med.* 25: 225-229, 1979.
7. Parashar SK: Echocardiographic diagnosis of left atrial myxoma: *Ind.Heart J.* 31: 50-57, 1979.

8. Feigenbaum H: Cardiac tumours, Echocardiography, Philadelphia: Lea and Febiger 1976, 447-462.
9. Demaria AN, Vismara LA, Miller RR, Neumann A, Mason DT: Unusual echographic manifestations of right and left heart myxomas. *Am.J. Med.* 59: 713-720, 1975.
10. Ghadda KD, Pochaczewsky R, Gupta PK, Lichstein E, Schwartz E: Non-prolapsing atrial myxoma: Clinical echocardiographic and angiographic correlations. *Angiology* 29: 176-186, 1978.
11. Stewart JA, Warnica JW, Kirk ME, Winsberg F: Left atrial myxoma: False negative echocardiographic findings in a tumor demonstrated by coronary arteriography. *Am. Heart J*: 98: 228-232, 1979.
12. Giuliani ER, Lemire F, Schattenberg TT: Unusual echocardiographic findings in a patient with left atrial myxoma. *Mayo Clinic Proc.* 53: 469-472, 1978 (Quoted by 15).
13. Kezber RE, Kelly DH, Jr., Gutenkauf CH: Left atrial myxoma. Demonstrated by stop action cardiac ultrasonography. *Amer J. Cardiol.* 34: 838-844, 1974.
14. Rogers EW, Weyman AE, Noble RJ, Bruins SC: Left atrial myxoma infected with *histoplasma capsulatum*. *Am.J.Med.* 64: 683-690, 1978.
15. Moses HW, Nanda NC: Value of real time two dimensional echocardiography in the diagnosis of left atrial myxoma. *Chest*: 78: 788-791, 1980.
16. Nanda NC, Gramiak R: Clinical echocardiography, St.Louis. The CV Mosby Co. 1978, 387, 411.
17. Harvey WP: Clinical aspects of cardiac tumors. *Am.J.Cardiol.* 21: 328-343, 1968.
18. Nasser, WK, Davis RH, Dillon JC, Tavel ME, Helmer CH, Feigenbaum H, Fisch C: Atrial myxoma. I clinical and pathologic features in nine cases, *Am. Heart J.* 83: 694-704, 1972.
19. Chaukar AP, Kale PA, Chaube RJ, Kinare SG, Parulkar GB, Sen PK: Myxoma of the left atrium. *J. Postgrad. Med.* 16: 156-159, 1970.
20. Dillon JC: Echocardiography in valvular vegetations. *Am.J.Med.* 62: 856-862, 1977.
21. Sharma S, Munsri SC, Bhattacharya SB: Value of echolucent areas detected by real time two dimensional echocardiography in differentiation of intracardiac mass lesions. *J. Cardiovascular Ultrasonography* 1: 20-21, 1982.