

# Percutaneous Balloon Pulmonary Valvuloplasty

AMAR LAL\*  
AZHAR FARUQUI\*  
KALIMUDDIN AZIZ\*

Percutaneous balloon pulmonary valvuloplasty has recently been developed as a safe procedure for relief of stenosed pulmonic valves. Recent reports suggest that it has become an established alternate procedure to open heart surgery for the management of pulmonary valve stenosis. Indeed it is now recommended as a procedure of first choice in the relief of congenital isolated pulmonary valve stenosis.

Initially Sem et al. (1) relieved the congenital pulmonary valve stenosis by pulling a carbon-dioxide filled balloon from the pulmonary artery into the right ventricle. But the method which was finally accepted, was the static balloon technique, reported by Kan and associates (2). Since then this technique has become the treatment of choice for valvular pulmonary stenosis (3,4,5,6). Balloon valvotomy has also been applied for congenital and rheumatic valvular aortic stenosis (9,10,11) with considerable success. Recently balloon valvotomy has been achieved for rheumatic and congenital mitral valve stenosis with encouraging results (12,13,14). The purpose of this report is to document the first successful application of pulmonic valve balloon dilatation technique in a 13 years old boy with severe pulmonary valve stenosis and mild infundibular stenosis at the National Institute of Cardiovascular Diseases.

## CASE REPORT

A 13 years old boy with a 2-year history of easy fatigability and shortness of breath on moderate to severe exertion, was referred from Peshawar for surgical pulmonary valvotomy.

On physical examination the pericardium showed right ventricular impulse with prominent 'A' wave in the jugular venous pulse. Second heart sound was single with a prominent S<sub>4</sub> at the left sternal border. There was an ejection systolic murmur of grade V/VI at the pulmonic area and was accompanied by a loud ejection click.

Electrocardiogram showed right ventricular hypertrophy and X-ray of the chest showed prominent pulmonary artery conus. A two D-echocardiography was done which showed thickened pulmonic valve and there was valvular doming during systole. The pulmonary root diameter at the level of valve insertion was 25 mm.

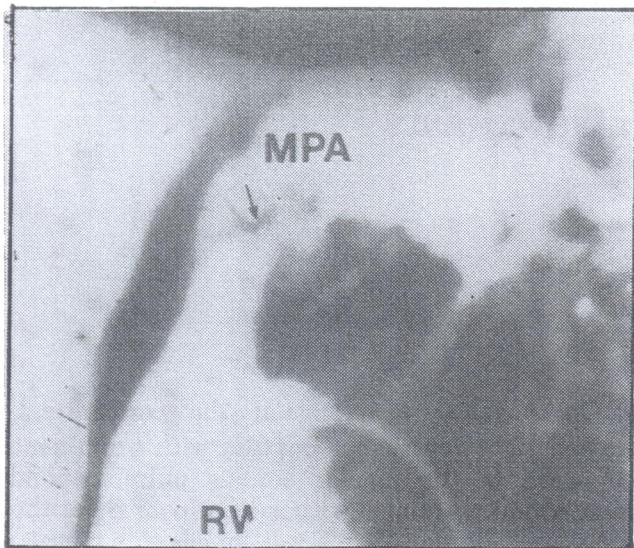
Cardiac catheterization was performed, which showed no oxygen step up in the right heart chambers. Right ventricular systolic pressure was 155mm Hg and pulmonary artery pressure was 19mm Hg. Thus a peak systolic pressure gradient of 136mm Hg was present across the pulmonic valve. Right ventriculogram demonstrated the doming of pulmonary valve in systole and significant post stenotic dilatation of the main pulmonary artery was present Fig 1. There was mild infundibular muscle stenosis and no atrial or ventricular septal defects were seen.

## Technique of balloon dilatation

The right ventricular cineangiogram was studied on video play back and the position and size of the pulmonic valve annulus was measured. A 0.035 inch 250cm J shaped exchange guide wire was passed through the right heart catheter into the left pulmonary artery and advanced well into left lower lobe of the lung. The catheter was then removed, leaving the guide wire stable in the left peripheral pulmonary artery. A soft lumen (blue) balloon valvuloplasty dilatation catheter

\* From: National Institute of Cardiovascular Diseases (Pakistan) Karachi.





Pre dilatation right ventricular (RV) cine angiogram, lateral view.

Note thickened stenotic pulmonic valve (arrows). Mild systolic infundibular narrowing is present and main pulmonary artery (MPA) is markedly dilated.

(Mansfield scientific Inc.) with a 20mm outer diameter and 3cm length was introduced percutaneously over the guide wire. To avoid air embolization in the event of balloon rupture, the balloon had been previously inflated and deflated several times at the inferior vena caval site with carbondioxide and with a 50/50 mixture of saline solution and renograffin 76 so that all air bubbles were removed. Balloon catheter was positioned fluoroscopically across the pulmonic valve and the balloon was rapidly hand inflated with a 30cc syringe, filled with 50/50 dye-dextrose solution until the waist of the balloon caused by the stenotic valve disappeared (figure 2). The balloon was rapidly deflated and placed in the main pulmonary artery. The procedure was repeated thrice after 5-10 minute interval till no visible waisting of the balloon could be observed on balloon inflation.

The balloon catheter was then replaced by a 7F balloon wedge catheter and right ventricular pulmonary artery pressures were recorded. A repeat right ventricular cineangiogram was performed with an angiographic catheter. The patient was ambulated on the next day and was discharged from the hospital on the same day.

**Immediate results.**

After the valve dilatation, right ventricular impulse was abolished and systolic ejection

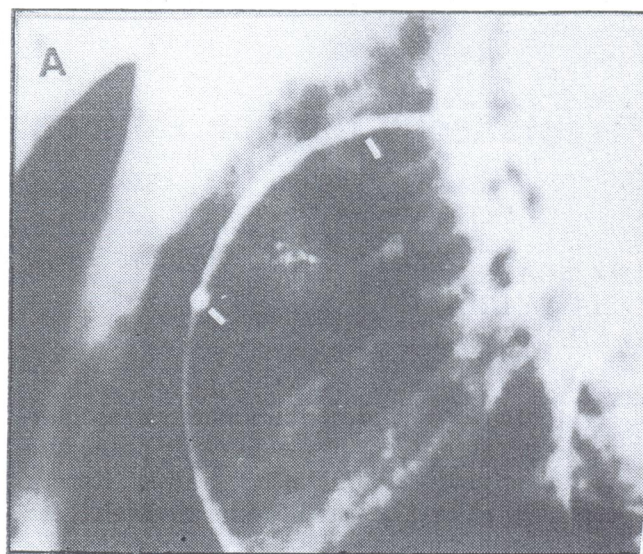


Fig 2 shows the position of the pulmonic valve which is approximately at the middle portion of the balloon length, indicated by white markers of the catheter (white bars).

murmur was gradeless and decreased in intensity and pulmonary click became faint. No diastolic murmur of pulmonary regurgitation was audible. The peak systolic pressure gradient across the pulmonary valve decreased from 136mm Hg to 41mm Hg, i.e. from severe to mild stenosis. Subjective angiographic comparison of valve opening and jet stream in the right ventricular cineangiogram, performed before and after the procedure, showed wider valve opening Fig 3.

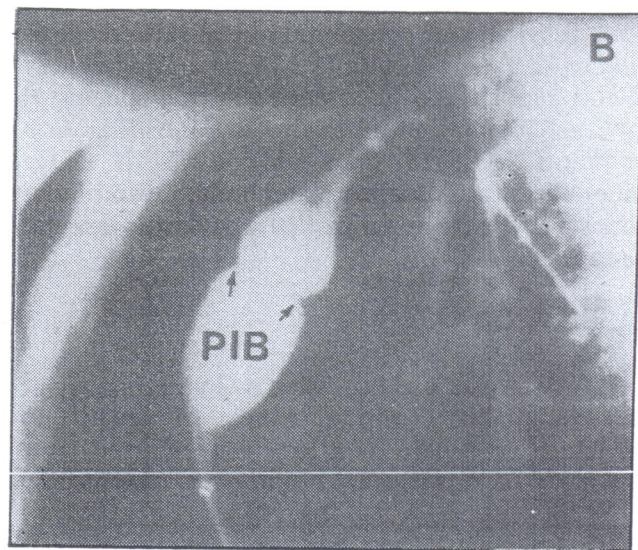


Fig 3. shows partially inflated balloon (PIB) and the indentation produced by the stenotic valve (arrows).



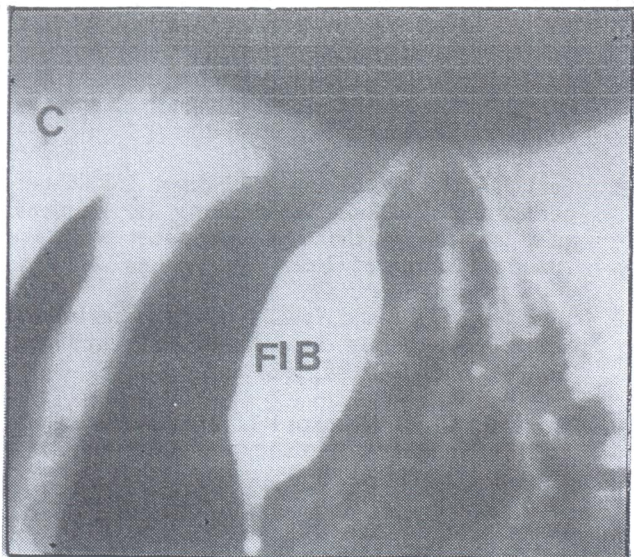


Fig 4. Shows fully inflated balloon (FIB) with complete disappearance of valve waist.

## Discussion

Isolated pulmonary valve stenosis is a common congenital cardiac defect and comprises about 10 per cent of all congenital heart diseases (15). In our own series of children under 12 years of age it had a similar incidence. Surgical valvotomy is well established and can be performed at low risk. However the surgical approach involves a sternotomy, open heart surgery and use of cardiopulmonary bypass, exposure to blood products, a surgical scar that is cosmetically displeasing and 2 weeks of hospitalization and approximate cost of 60,000 rupees.

Balloon pulmonary valve dilatation is an alternate and safe method, and can be performed in cardiac catheterization laboratory as a part of routine catheterization procedure without general anaesthesia and requires 2-3 days hospitalization. The reported experience shows that successful balloon dilatation of the pulmonic valve can be undertaken without mortality even when congestive cardiac failure is present, as can be the case in small infants with critical isolated pulmonary stenosis. The physical principles governing the balloon dilatation depends upon the transmission of controlled radial force through a rigid balloon, while mechanism of relief of obstruction of the congenital stenotic valve is a commissural split of the fused valve cusps.

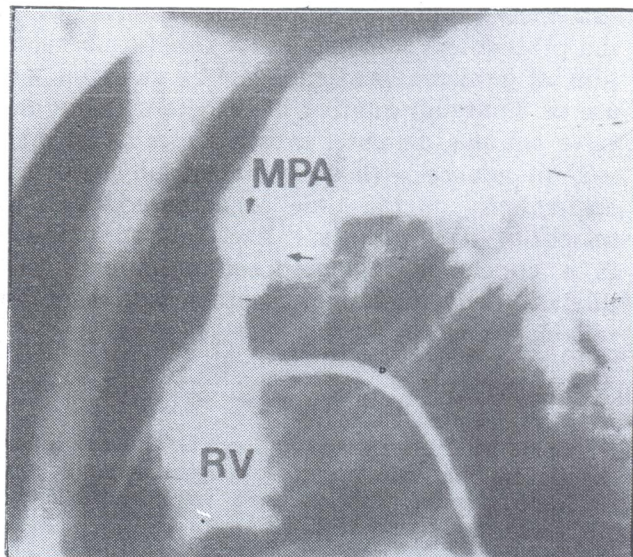


Fig 5. Right ventricular (RV) cine angiogram, lateral view, after pulmonary valve dilatation.

Note anterior leaflet of pulmonic valve is irregular due to tear of dilatation (arrow).

At present, the use of large balloon catheters have been approved by food and drug administration in the USA only for pulmonary balloon valvuloplasty. A 3cm long balloon whose outer diameter is 120 per cent of the pulmonary valve annulus is chosen as the initial catheter for the children with mild or moderate pulmonary stenosis. For severely narrowed pulmonary valves, balloon should be about the size of the pulmonic valve annulus. In young adults the pulmonary valve annulus diameter is usually larger than 20cm thus balloon of larger size may be required or two comm outer diameter balloons may be placed in the annulus and simultaneously inflated (7). Balloon dilatation can be performed at any age in infants as small as 3kg. The application of this procedure will require careful selection of patients. Isolated pulmonary valve stenosis is the absolute indication with peak systolic pressure gradient across the pulmonary valve should be greater than 40mm Hg. The results of dilatation show that pressure gradient can be effectively reduced in most cases (2,3,5,6,7,8) with no mortality or any complication such as pulmonary regurgitation. Patients who have dysplasia of pulmonary valve may not benefit as much from this procedure. The procedure is also not recommended for the patients with combined pulmonary and infundibular stenosis, because of high risk of cusp avulsion. Finally the cost of balloon catheter is around 6,000 to 8,000 Rupees. It is, therefore,



extremely important for us to follow strictly the protocol so that maximum benefit, i.e. reduction of pressure gradient, can be achieved with use of minimum number of catheters. Pulmonary valve annulus diameter estimation must be made well in advance with echocardiography and with angiography at the time of catheterization for selection of appropriate size balloon catheter. It is concluded that stenosed pulmonary valve dilatation by balloon catheters is a safe and reliable procedure.

#### REFERENCES:

1. Semb BKH, Tjonneland S, Stake G, and Aabyholm G; balloon valvotomy of congenital pulmonary valve stenosis with tricuspid valve insufficiency. *Cardiovasc. Radiol* 2: 23-9-241, 1979.
2. Kan JS, White RL Jr, Mitchell SE, Anderson JH, and Gardner TJ; percutaneous balloon valvuloplasty. A new method for treating congenital pulmonary valve stenosis. *New Eng. J. Med* 307: 540-542, 1982.
3. Kan JS, White RL Jr, Mitchell SE, Anderson JH, and Rosenthal A; percutaneous balloon valvuloplasty for treatment *Coll. Cardiol.* 3: 1005-1012, 1984.
4. Rocchini AP, Keselis DA, Crowley D, Dick M, and Rosenthal A; percutaneous balloon valvuloplasty for treatment *Coll. Cardiol.* 3; 1005-1012, 1984.
5. Labadibi Z, and Wu J; percutaneous balloon pulmonary valvuloplasty. *Am J, Cardiol.* 52: 560-562, 1983.
6. Radtke W, Keane JF, Fellows KE, Lang P, and Lock JE; percutaneous balloon valvotomy of congenital pulmonary stenosis using oversized balloons. *J Am. Coll. Cardiol.* 8: 909-915, 1986.
7. MA Ali Khan, Saad Al-Yousuf, Charles E, Mullins; percutaneous transluminal balloon pulmonary valvuloplasty for the relief of pulmonary valve stenosis special reference to double balloon technique, *American Heart Journal*, July 1986.
8. Carl J. Pepine, Ira H. Gessner, Robert L Feldman; percutaneous balloon valvuloplasty for pulmonic valve stenosis in the adult, December 1982, the *American Journal of Cardiology*, Volume 50.
9. Labadibi Z, Wu J, and Walls JT; percutaneous balloon aortic valvuloplasty in infancy and childhood. *Am J, Cardiol.* 53: 194, 1984.
10. Rupprath G, and Neuhaus KL; percutaneous balloon aortic valvuloplasty in infancy and childhood. *Am J. Cardiol.* 55: 1856-1985.
11. Helgason H, Keane JF, Fellows KE, Kulik TJ, and Lock JE; balloon dilatation of the aortic valve; studies in normal lambs and in children with aortic stenosis. *J Am, Coll. Cardiol.* In press.
12. Inoue K, Owaki T, Nakamura T, and Miyamoto N; clinical application of transvenous mitral commissurotomy by a new balloon catheter. *J Thorac, Cardiovasc. Surg.* 87: 394-402, 1984.
13. Lock JE, Khalilullah M, Shrivastava S, Bahl V, and Keane JF; percutaneous catheter commissurotomy in rheumatic mitral stenosis. *New Eng. J. Med.* 313: 1515-1519, 1985.
14. Palacios IF, Lock JE, Keane JF, and Block PC; percutaneous transvenous balloon valvotomy in a patient with severe calcific mitral stenosis. *J. Am, Coll. Cardiol.* 7: 1416-1419, 1986.
15. Keith JD, Row RD, Vlad P; heart disease in infancy and childhood 3rd ed. New York, Macmillan. 761-788. 1979.

