

Radiology Of The Heart

SULTAN AHMED SHAH

In spite of the universal availability of radiological facilities this simple investigation has been rather underutilised in assessment of cardiac diseases.

Advanced haemodynamic studies, no doubt may be essential for more precise information as a pre-requisite to surgical correction, but a correct diagnosis can be inferred in most of the cases by plain chest X-Ray in P.A. and left lateral view. Additional views may be taken for further confirmation of diagnosis if and when necessary.

The Technique: of the chest X-Ray does not differ from that employed in evaluation of pulmonary diseases. Both views should be taken at a distance of 6 feet during the middle phase of respiration and if desirable thick barium may be swallowed to outline the oesophagus for various measurements.

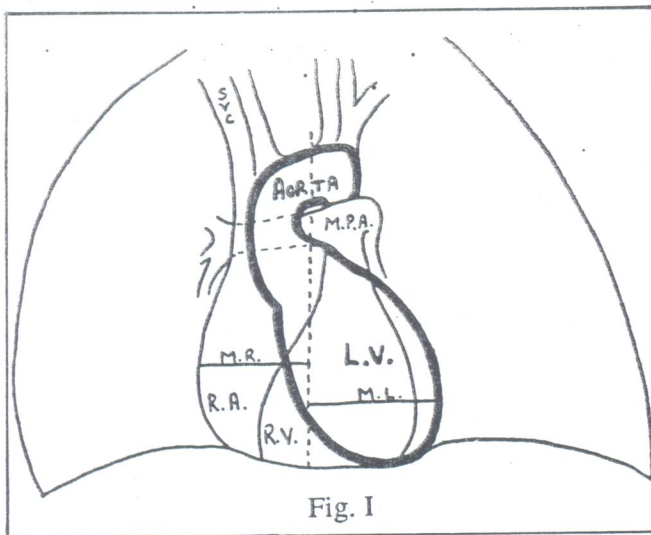


Fig. I

Fig. I illustrates the radiological anatomy of heart in P.A. view. The right border is formed mainly by the right atrium with superior vena cava contributing to the upper portion and inferior vena cava forming the lower most part only during deep inspiration. The left border consists of three well defined segments formed

Pearls from The Past
Issues of P.H.J.
Volume 13 No. 2
April-June, 1980

from above down by the end-on appearance of Aorta, left pulmonary artery and left ventricle respectively.

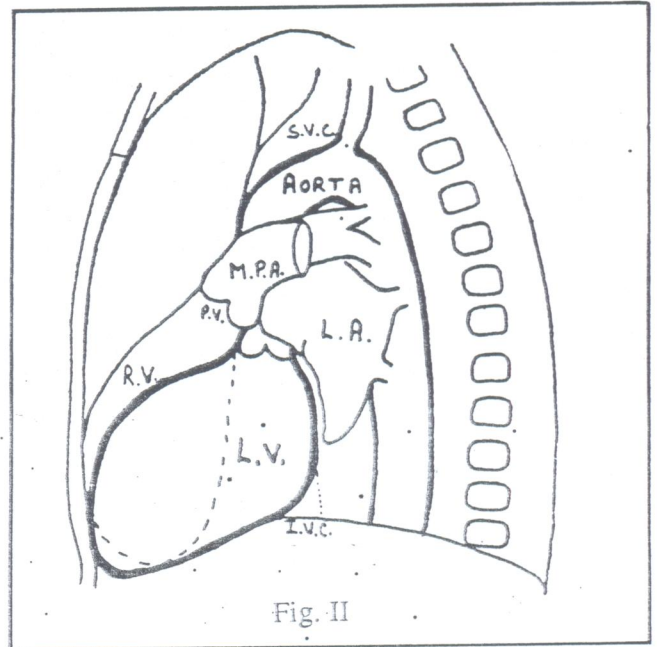


Fig. II

In the left lateral view (Fig. II) the following structures outline the Cardiac shadow:-

1. Anterior upper border from above down:
 Superior Vena Cava
 Ascending Aorta
 Pulmonary Trunk.
2. Anterior lower border:
 Right Ventricle.
3. Posterior upper border:
 Left Atrium
 Pulmonary Veins.
4. Posterior lower border:
 Left Ventricle
 Inferior Vena Cava.

The enlargement of the heart is measured by increase in the ratio of transverse cardiac diameter (T.D.) to trans-thoracic diameter which is normally under 1/2. Transverse diameter is the sum of maximum projection on the right and left border from mid line (Fig. I).

The enlargement of individual chamber may be recognized by the following changes:

Left Ventricle: In P.A. view there is elongation of the left border and depression of left diaphragm (Fig. III). In left lateral view the enlarged left ventricle extends beyond in the retrocardiac space which is more obvious in left anterior oblique view where it encroaches on the spine as well (Fig. IV).

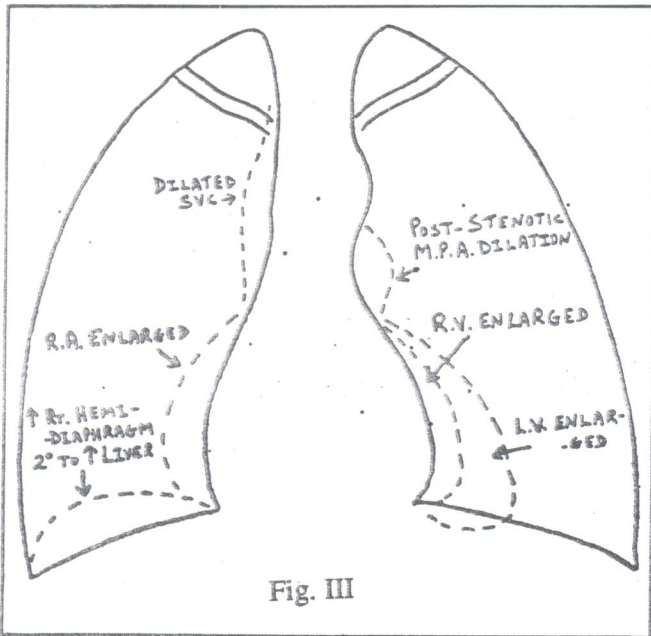


Fig. III

Right Ventricle: In P.A. view the left ventricle is tilted up and another contour of right ventricle appears in between the left ventricle and diaphragm, occasionally the right border of heart may bulge out due to displacement or right atrium (Fig. III). In left lateral view the right ventricle bulges anteriorly and climbs upwards so that the lower half or more of the sternum is in direct contact with right ventricle instead of the lower one third (Fig. V) in normals.

Left Atrium: This can enlarge more than any other cardiac chamber due to its thin walls, anatomic position, lack of valves between it and the pulmonary vein

and the fact that both ventricles pump blood into it in mitral insufficiency (Sloan 1954). It enlarges first posteriorly which is best seen in R.A.O. position (Fig. VI), then to right—left—superiorly (Fig. VII).

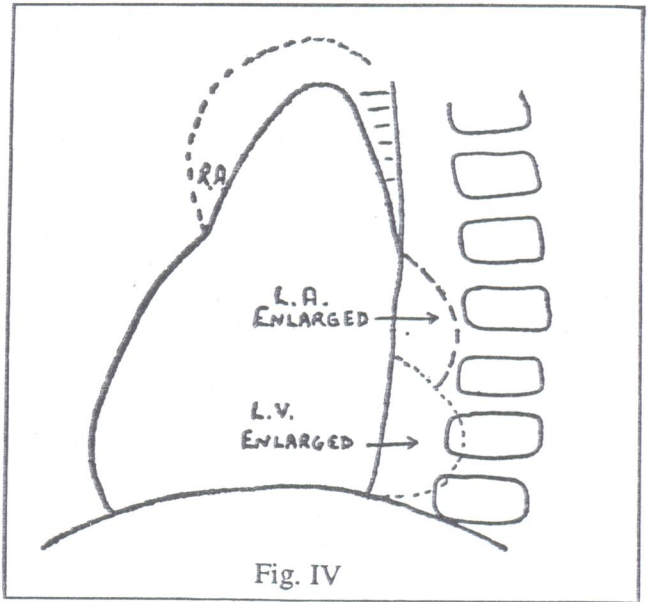


Fig. IV

Right Atrium: Enlargement of right atrium manifests on P.A. view by increase convexity of right border, widening of the shadow of superior vena cava and elevation of right hemidiaphragm due to hepatomegaly (Fig. III). In the left anterior oblique view (Fig. IV) the enlarged right atrial appendage area imparts a square shaped appearance to the anterior border. In right anterior oblique view (Fig. VII) the main body of right atrium projects behind the oesophagus.

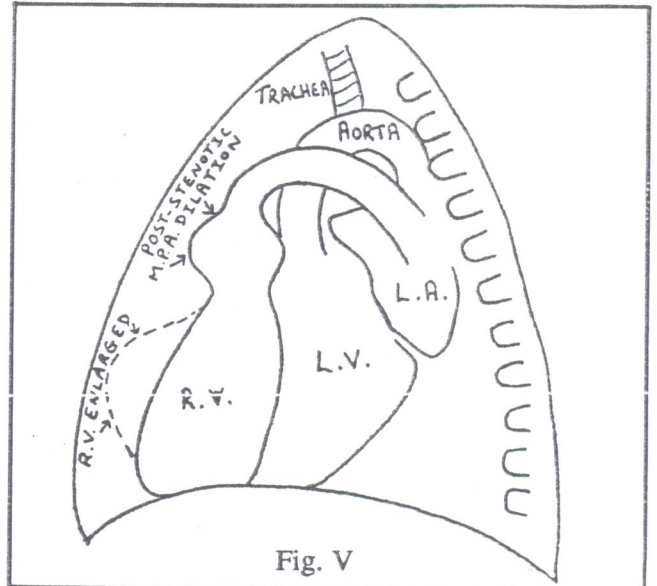


Fig. V

After ascertaining the chamber of heart predominantly enlarged, the final diagnosis is made in conjunction with other available evidences.

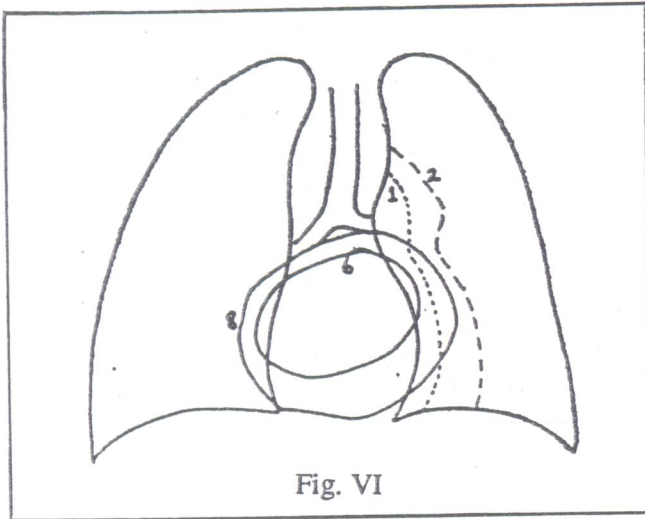


Fig. VI

Thus, in aortic valvular disease apart from left ventricular enlargement there may be calcification of valve and dilatation of aorta. In mitral disease there will be left atrial enlargement with additional changes in the lung and right ventricle in stenosis, and left ventricular enlargement in incompetence.

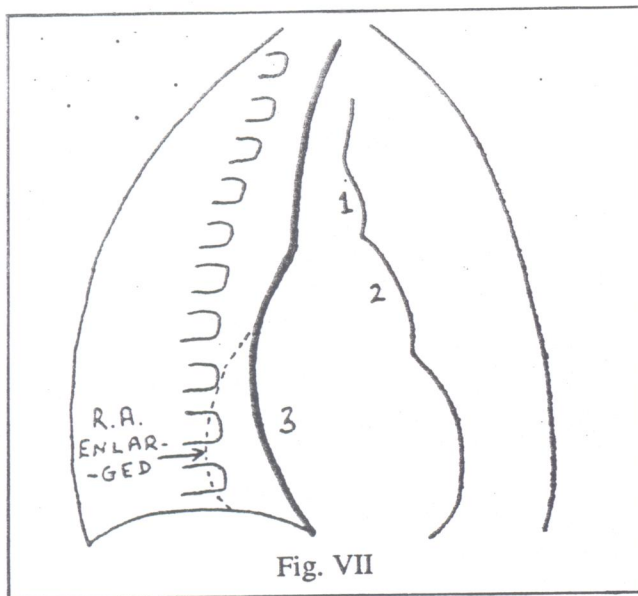


Fig. VII

Pulmonary Vascular Patterns:

Pulmonary Venous Patterns: These reflect the functional aspect of left side of the heart for which it has great diagnostic implication.

The veins can be distinguished from the arteries in the upper lobe by their more lateral location though they cross at hilum to acquire its upper portion. In lower lobe the veins are more horizontal and join perpendicularly in the pericardium. The venous pressure is normally under 10 mmHg but may rise with rise in left ventricular end-diastolic pressure or secondary to obstruction in pulmonary veins, left atrial in-flow or out-flow tract. If the pressure is raised to less than 20 mm then there is reflex narrowing of lower zone vessels and dilatation of upper lobe vessels. With further rise of pressure upto 30 mm the lower lobe vessels assume normal calibre but the upper lobe vessels remain dilated. Interstitial oedema and small pleural effusion may also appear then. In situations associated with abrupt rise of pressure beyond 30 mm, alveolar oedema characterized by confluent lung shadow and large pleural effusion may be seen. When the rise in pressure is more inceptient, perivascular shadows become hazy giving a ground-glass appearance. Septal lines (Kerley's) can also be seen then due to collection of fluid in interalveolar septae. The Kerley's B-lines are 4 mm wide and perpendicular to pleura, 'A' lines run towards the hilum about 4 cm in length. The Kerley's 'C' lines are much finer and shorter can go in any direction. Fig. VIII illustrates the above radiological signs as well as the other radiological features associated with congestive cardiac failure.

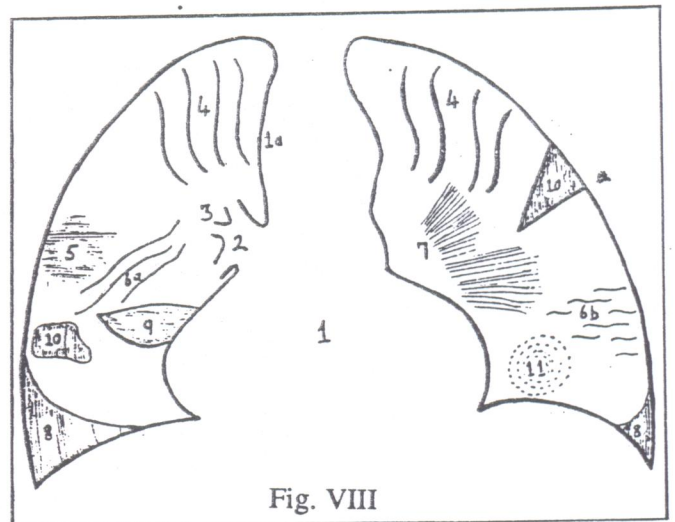


Fig. VIII

Initially, the cardiac contour is well maintained so that the predominantly affected cardiac chamber can be identified. Dilatation of hilar vessels leads to their further extension in the lung field. Hilum may appear

Table I Congenital Heart Disease: Pulmonary Vasculature

<i>Diminished</i>		<i>Normal</i>		<i>Increased</i>		
Right ventricle predominant	Left ventricle predominant	Right ventricle predominant	Left ventricle predominant	Right ventricle predominant	Left ventricle predominant	
Acyanotic Pulmonary stenosis, no right to left shunt Congenital absence of pulmonary artery		Pulmonary stenosis, no right to left shunt	Coarctation of aorta Aortic or sub-aortic stenosis I-V septal defect (small) myocardial or endocardial disease. Primary endocardial fibro-elastosis (with and without associated valve defects)	Partial pulmonary vein anomaly Atrial septal defect Lutembacher's Syndrome A-V communis Pulmonary hypertension with I-V septal defect or patent ductus, (Eisenmenger complex) Patent ductus right to left shunt)	Patent ductus (left to right shunt) Aorto-pulmonary window A-V communis I-V septal defect (moderate) Endocardial fibroelastosis	
Cyanotic Pulmonary stenosis with right to left shunt due to: Atrial septal defect; tetralogy (I.A. septal defect) Ventricular septal defect: tetralogy (I.V. septal defect) Pulmonary stenosis plus transposition Pulmonary stenosis plus single ventricle Peripheral pulmonary vessel obstructions.		Tricuspid atresia Pulmonary stenosis plus single ventricle Ebstein's disease		Total pulmonary anomaly Transposition (no pulmonary stenosis) Taussig-Bing syndrome Single ventricle (no pulmonary stenosis) Truncus arteriosus Aortic atresia Pulmonary vascular obstruction secondary to A-V communis, I-V septal defect, Patent ductus		

Inversions of Cardiac Image or Chambers: Situs inversus and dextrocardia Corrected transposition.

Cyanotic

Acyanotic

enlarged due to perivascular oedema which may make the identification of the arteries and vein in the hilum difficult. The haziness of the lung field may be due to interstitial oedema.

Pulmonary Arterial Patterns: These depend on the amount of pulmonary blood flow which may be decreased in obstructive disease of the right ventricular outflow tract, and increased in left to right shunts.

The right pulmonary artery runs horizontally to the right in the mediastinum and as such it is invisible on P.A. view though on lateral view it may appear as an end-on vessel. Left pulmonary artery is visible because it traverses from front to back in the hilum.

The descending pulmonary artery, the main branch of the main pulmonary artery is visible in P.A. view on both sides as it passes from its origin in the hilum downward and outward, lateral to the cardiac border. It is upon the thickness of the artery and the pattern of the distribution of peripheral arteries that the grading of plethora is done in the following three grades.

1+: The size of the descending pulmonary artery is greater than 16 mm which is the maximum permissible normal limit. 2+: The size of the descending artery is increased and tapers evenly to the periphery 3+: The torrential blood flow has stretched the peripheral muscular vessel leading to their abrupt narrowing at segmental level so that the even narrowing is lost, though the normal ratio between the central and peripheral vessel is maintained within normal limits of 5:1. In pulmonary arterial hypertension associated with pressures exceeding 50/25 mm Hg there is marked dilatation of central vessel upto the segmental level thereby increasing the ratio of thickness of hilar vessel to

peripheral vessel to 7:1. Pulmonary oligemia is characterised by diminution in shadow of both arteries and veins which makes the lung more radiolucent. No pulsation of the hilar vessels is seen on image-intensification fluoroscopy.

On the basis of the pulmonary vasculature, the cardiac chamber predominantly affected, the presence or absence of cyanosis, congenital heart diseases can be divided into twelve subgroups: (Table I).

It must be admitted that the possibility of reaching an exact diagnosis by plain X-Ray of chest alone is much more in acquired heart disease than congenital heart disease where one has to be satisfied by placing them in one of the above twelve subgroups (Table I) as the anatomical abnormalities may be multiple. However, the radiographic picture coupled with other clinical features and the frequency of occurrence of a disease makes possible very sophisticated diagnosis. The X-Ray chest is the cheapest and rupee for rupee most useful non-invasive cardiac diagnostic test available.

References:

1. Heart Disease, Silber, E.N. and Katz L.N. Macmillan 1977.
2. The Heart edited by Hurst, J. Willis (et. al.) McGraw Hill, 1978.
3. Roentgen Signs in clinical Practice by Meschan Isadore, Vol. II, Saunders, 1966.
4. Clinical Cardiac Radiology by Jefferson, Keith and Rees Simon. Butterworths, 1978.
5. Clinical Anatomy of the Heart, by Walmsley, Robert IIIrd Watson, Hamish Churchill, 1978.