

# How To Exchange A Thrombus Occluded Arterial Catheter During Cardiac Catheterization And Angiography\*

## Experience With Modified Guide Wire Method

SHABBIR HUSSAIN SHEIKH  
MOHAMMAD ASHRAF DAR  
MOHAMMAD ZUBAIR

### INTRODUCTION

Occlusion of an arterial catheter is rare but well-known complication during Cardiac Catheterization. This condition is easily recognized by inability to aspirate blood from the catheter. When this occurs, do not attempt to clear the occluded catheter by forcing flushing solution or contrast medium through it, but instead try to figure out why the catheter has become occluded. This could be simply due to selective wedging of the catheter tip in a small vessel: just withdraw the catheter and try to aspirate blood, most of the time this can be readily aspirated. If blood does not come out by aspirating, you must think of a thrombus occlusion.

Two methods have been published in literature regarding the exchange of thrombus-occluded arterial catheter.

1. Sheath Method.
2. Guide Wire Method.

Sheath Method is easy. You just pass an appropriate size sheath over the catheter after cutting the proximal end of the occluded catheter. It has two main disadvantages.

1. The Sheath makes a large hole in the artery.
2. There is greater need to flush the space between the sheath and the catheter with a heparinised flushing solution to prevent clot formation.

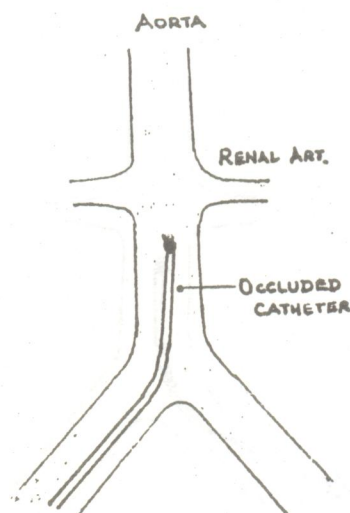
Our experience with guide wire method is much more encouraging.

### GUIDE-WIRE METHOD (MODIFIED)

Although a guide-wire cannot be passed through the occluded catheter, it can still be used to exchange the catheter.

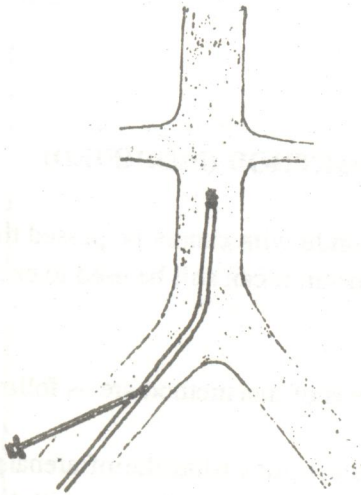
Different Steps of this method are as follows:-

1. Pull the catheter tip down into the infrarenal portion above the bifercation of aorta. Do not withdraw the Catheter-tip down into either femoral or iliac arteries, as the catheter has to advance again into the abdominal aorta; it may not pass back up without the help of guide wire if withdrawn too far in the femoral artery (Fig. 1).

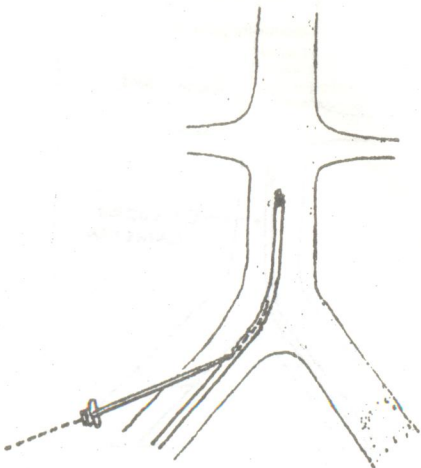


\* Cardiology Department, Mayo Hospital, Lahore - Pakistan.

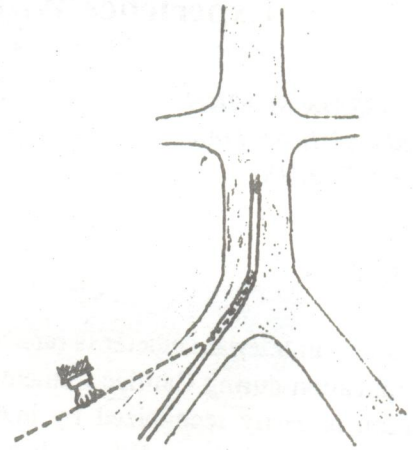
2. Puncture the Catheter close to the entry point with a seldinger needle as in seldinger's technique used to puncture the native artery (Fig. 2).



3. Pass the soft end of the guidewire through the needle only for a small distance (2cm); do not advance upto the level of obstruction (Fig. 3).

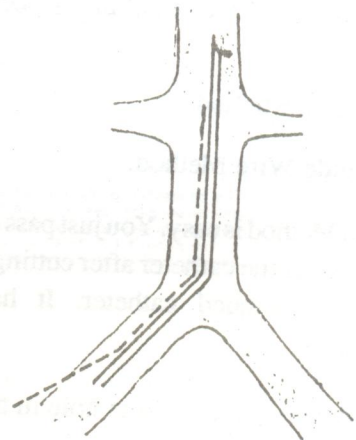


4. Now remove the seldinger needle while keeping the guidewire in position (Fig. 4).



5. Now pass the guidewire and the catheter together as a unit into the femoral artery, and up into the abdominal aorta under fluoroscope.

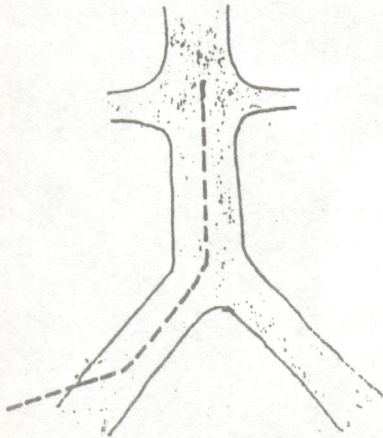
6. Once the guidewire is seen under the fluoroscope to lie within the abdominal aorta, two methods can be used to separate the guidewire from the catheter (Fig. 5).



a). Hold the guidewire at inguinal region with your left hand and advance the catheter further up in the aorta. This manoeuvre will dislodge the guidewire from the catheter lumen and the guidewire will lie free in the abdominal aorta.

b). Once the guidewire is seen in the abdominal aorta under fluoroscope, just withdraw the guidewire; it will come out of the catheter hole and will lie free in the abdominal aorta (Modified Guide Wire Method).

7. Now the occluded catheter can be withdrawn easily while keeping the guidewire in the abdominal aorta (Fig. 6).



8. The new Catheter can now easily be advanced on the guidewire in the usual manner.

This method requires careful catheter-guidewire manipulation and close fluoroscopic monitoring. The main advantages of this method are the elimination of a large hole in the artery caused by the sheath method and eliminating the need for an additional arterial puncture.

We use the modified method to exchange the occluded catheter and found it to be an excellent procedure. We faced this problem only in four patients within last four years while doing coronary angiography.

It is a simple, time saving procedure and can be used when faced with this problem. Prevention of this problem lies in regular flushing with heparinized dextrose or saline solution, or filling the catheter with non-ionic contrast media.

#### REFERENCES:

Amil J. Gerlock, JR., M.D, et al: Shreveport, Louisiana.

Essentials of Diagnostic and Interventional Angiographic Techniques 1985 23-26.

