

## LEARNING CORNER



## SECTION EDITOR

**Fathe Ali Tipoo Sultan**

Aga Khan University Hospital, Karachi,  
Pakistan

Dr. Tipoo is currently working as Associate Professor and Consultant Cardiologist at Aga Khan University Hospital, Karachi.

## YOUNG MAN WITH PRODUCTIVE COUGH AND RIGHT SIDED HEART

**Imran Hameed<sup>1</sup>**

<sup>1</sup>Anklesaria Nursing Home, Karachi, Pakistan

### SUMMARY

Case of a young man who presented with repeated episodes of productive cough and shortness of breath. Clinical and non-invasive evaluation revealed situs inversus, dextrocardia, features of bronchiectasis and lung cysts along with immotile sperms on semen analysis. A diagnosis of Kartagener's syndrome was established. Genetic study could not be done due to financial restraints. Regular chest physiotherapy, antibiotics and bronchodilators were advised with close follow-up.

### CLINICAL VIGNETTE

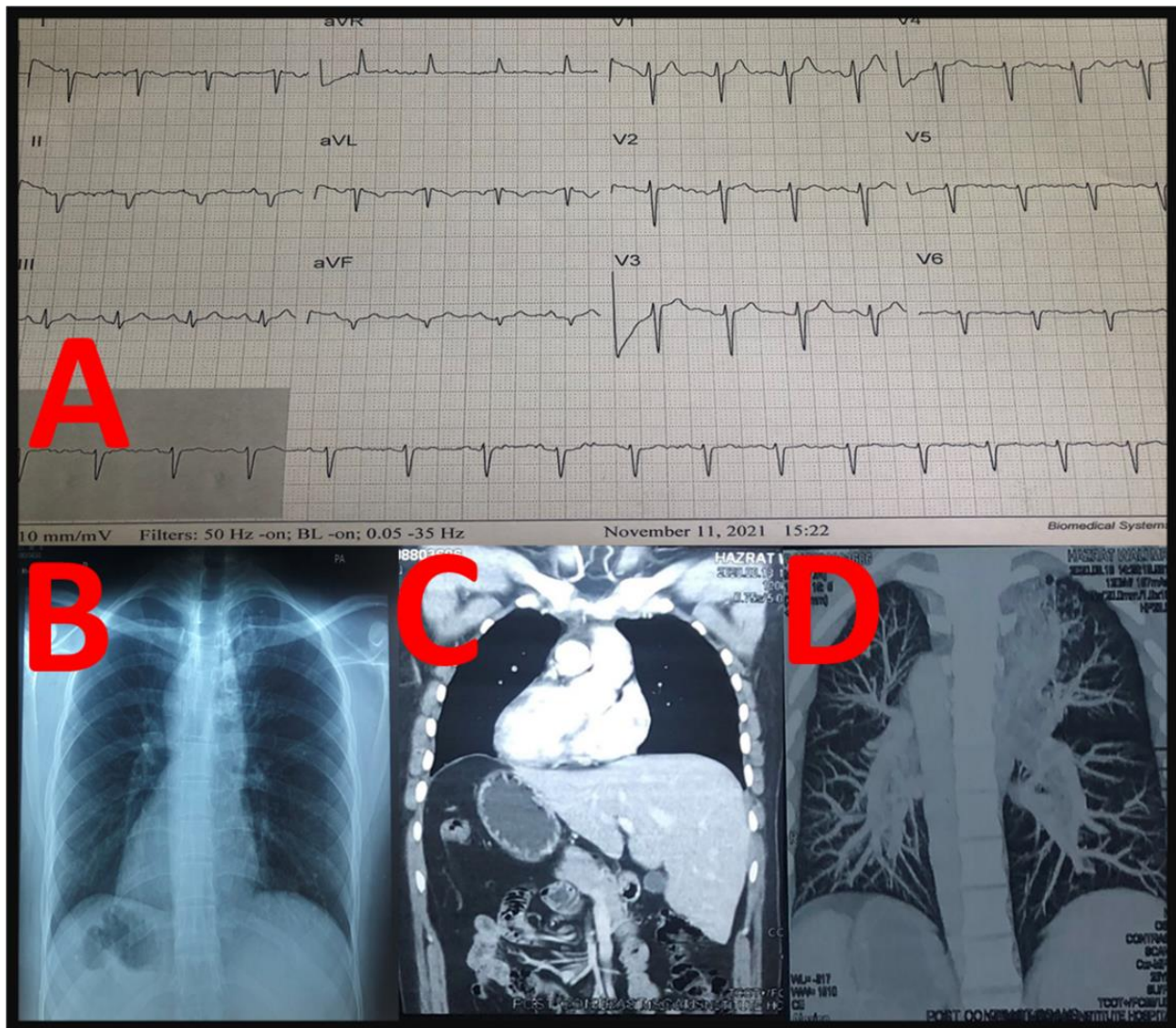
A 25 years old male presented with repeated episodes of cough and sputum production dating back to infancy. On examination patient was vitally stable with mild tinge of cyanosis. CVS examination showed a right sided apex in 5th intercostal space with no added sound or murmur. Resting 12 lead ECG showed Situs inversus with features of dextrocardia (panel A Figure 1). Routine chest X-ray PA view revealed situs inversus (stomach bubble under right hemi-diaphragm) and dextrocardia with normal heart size and increased broncho vascular markings in left upper zone (Panel B, Figure 1). A paranasal sinus X-ray showed congested turbinates, thickened mucosa of both maxillary sinuses with fluid. Hemoglobin was 15.7 g/dl whereas the white cells and platelet counts were normal. Blood chemistry was un-remarkable. Pulmonary Function test showed vital capacity (VC) of 3.48 l (78% of predicted), forced vital capacity (FVC) of 3.5 l (81% of predicted), forced expiratory volume in 1 sec (FEV1) 2.94l (81% of predicted), and peak expiratory flow rate (PEFR) of 5.41 l/s (57% of predicted). An HRCT chest confirmed the findings of situs inversus and dextrocardia and lung windows showed linear branching with small nodules giving 'tree in bud appearance' in left upper and right middle lobes

(bronchopneumonia) and cystic changes in left upper lobe posterior segment (bronchiectasis). A semen analysis revealed normal sperm count (20 million/ml) with 100 % immotile (both progressive and non-progressive being zero), 15% of sperms had normal morphology whereas of the 85% abnormal forms, head defect (55%), mid-piece defect (20%) and tail defect (10%) were noted.

### DISCUSSION

Kartagener's syndrome is a rare genetic recessive disorder.<sup>1</sup> It affects 1 in 20-30,000 live births.<sup>2</sup> The involved genes are DNAI1 and DNAH5 DNAH1, DNAI2, KTU, RSPH9, RSPH4A, and TXNDC3.<sup>3</sup> The main effect is on ciliary motion, an impairment of which leads to sinopulmonary infections, infertility and inverted visceral orientation. Diagnosis depends on a triad of features with additional finding of alive but immotile sperms.

The case under discussion showed all the relevant features for diagnosis. He was suggested for left upper lobectomy of lung but in view of non-localized nature of disease, the thoracic surgeon didn't force for it, as chances of post-operative respiratory complications (exacerbation of infections, difficulty in achieving good bronchial toilet in the presence of endotracheal tube etc.) were expected to be high. Hence a conservative course was adopted.



**Figure 1: Kartagener's syndrome: Panel A- ECG. Panel B- Chest X-ray PA view. Panel C- Coronal section of CT Scan of Chest and abdomen and Panel D- Contrast enhanced CT of chest**

#### QUESTION 1

In Kartagener's syndrome the proportion of patients (adults) showing laterality defects (right-left orientation of viscera) is:

- A. 20%
- B. 30%
- C. 40%
- D. 50%
- E. 60%

#### QUESTION 2

In Kartagener's syndrome, bronchiectasis usually affects;

- A. Middle lobe
- B. Upper lobes
- C. Lower lobes

- D. No preference for lobes
- E. Middle and lower lobes

#### QUESTION 3

The gas measured in breath test for the diagnosis of Kartagener's syndrome?

- A. Oxygen
- B. Carbon dioxide
- C. Nitric Oxide
- D. Helium
- E. Nitrogen

**QUESTION 4**

The gold standard diagnostic test for Kartagener's syndrome at present is:

- A. Genetic testing
- B. Ultrastructural electron microscopic examination of nasal cilia.
- C. CT scan of chest
- D. Sperm analysis
- E. Clinical history

**LEARNING POINTS**

1. Patients with situs inversus and respiratory symptoms must be evaluated for Kartagener's syndrome.
2. Kartagener's syndrome is a rare genetic recessive disorder of cilia affecting 1 in 20-30,000 live births. Nine genes (to date) have been associated with this disorder.
3. Chronic sinusitis, bronchiectasis and situs inversus is the triad for diagnosis.
4. 25% of patients with situs inversus show features of Kartagener's syndrome.
5. Differential diagnoses include "malignancy, interstitial lung diseases, bronchiectasis, congenital

bronchial obstruction, recurrent infection (immunodeficiencies), abnormal secretion disorder (cystic fibrosis), and other miscellaneous conditions (alpha-1 antitrypsin deficiency and connective tissue disease)<sup>3,4</sup>

6. Surgical correction for lung involvement should be done only in localized cases at specialized centres.

**REFERENCES**

7. Tadesse A, Alemu H, Silamsaw M. Kartagener's syndrome: a case report. J Med Case Reports. 2018;12:5
8. Abbasi MA, Suleman A, Ahmed N, Zaman H. Kartagener syndrome: a not so rare phenomenon. J Ayub Med Coll Abbottabad. 2014;26(4):598-601.
9. Leigh MW, Pittman JE, Carson JL, Ferkol TW, Dell SD, Davis SD, et al. Clinical and genetic aspects of primary ciliary dyskinesia/Kartagener syndrome. Genet Med. 2009;11(7):473-87.
10. Nedaa S, Fadi II. Kartagener syndrome. Int J Gen Med. 2011;4:41-3.

**ANSWERS**

- *Question 1:* D
- *Question 2:* E
- *Question 3:* C
- *Question 3:* B

**Citation:** Hameed I. Young Man with Productive Cough and Right Sided Heart. Pak Heart J. 2022;55(01):96-98. DOI: <https://doi.org/10.47144/phj.v55i1.2261>

**Address for Correspondence:**

**Dr. Imran Hameed**, Consultant Cardiologist, Anklesaria Nursing Home, Karachi, Pakistan.

**Email:** [imranhameed61@hotmail.com](mailto:imranhameed61@hotmail.com)