

CASE REPORT**MALIGNANT MULTI-VESSEL CORONARY ARTERY SPASM; A RARE CAUSE OF MYOCARDIAL INFARCTION LEADING TO CARDIOGENIC SHOCK – A CASE REPORT**

Jehangir Ali Shah¹, Nasir Ali¹, Bashir Ahmed Solangi¹, Kamran Ahmed Khan¹, Rajesh Kumar¹, Tahir Saghir¹

¹National Institute of Cardiovascular Diseases (NICVD), Pakistan

Malignant multi-vessel coronary vasospasm is a rare life threatening condition, presentation like myocardial infarction (MI), arrhythmias, and cardiogenic shock (CS). We report a case of IWMI complicated by CS, angiogram shows diffuse multi-vessel coronary artery spasm. Intracoronary nitroglycerine showing improving spasm in culprit vessel RCA and distal RCA stented with excellent result. This case of early diagnosis of coronary artery spasm to prevent the occurrence of MI, arrhythmias and sudden cardiac death as it is one the rare cause. It also highlighted the role of intracoronary nitroglycerine in relieving diffuse multi-vessel vasospasm in hemodynamically unstable patient.

Keywords: cardiogenic shock, myocardial infarction, coronary vasospasm, multi-vessel, arrhythmias, case report

Citation: Shah JA, Ali N, Solangi BA, Khan KA, Kumar R, Saghir T. Malignant Multi-vessel Coronary Artery Spasm; a Rare Cause of Myocardial Infarction Leading to Cardiogenic Shock – a Case Report. Pak Heart J. 2022;55(01):89-91. DOI: <https://doi.org/10.47144/phj.v55i1.2136>

INTRODUCTION

Coronary artery spasm (CAS) is an uncommon condition with rarely complicating as Myocardial infarction, arrhythmias, cardiogenic shock and sudden cardiac death. This disease has racial heterogeneity and is more common in Asians mainly Japanese.¹

CAS is a severe reversible diffuse or focal vasoconstriction of coronary vessels for which the exact mechanism is not clear but coronary muscle hyperactivity is thought to be one of the main mechanisms, there are no known causes of this disease but smoking and migraine has some association with stress, cocaine, alcohol and ergot alkaloids are some of the aggravating factors.²

The clinical presentation of CAS mimic angina with chest pain, nausea and cold sweats but it can also complicate into life threatening conditions.³

Its management is life style modification by avoiding modifiable risks factors i.e. smoking cessation, alcohol, cocaine and ergot alkaloids and medicinal treatment by using calcium channel blocker, Aspirin and nitrates.² Here we are presenting a case of 70 year old male diagnosed as Inferior wall STEMI and cardiogenic shock with diffuse multiple coronary vasospasm on Angiography.

CASE REPORT

This is a case of 70 year old male known case of hypertension (HTN) and diabetes mellitus (DM) on

oral hypoglycemic and antihypertensive medications presented to Emergency department with complain of chest pain from 8 hour. Written consent for the reporting of this case report was obtained from the patient. Pain is continuous and severe in intensity and it was non-radiating, he had a history of admission with unstable angina and underwent coronary angiography that revealed three vessel coronary artery disease, heart team discussion advised CABG (Figure 1A).

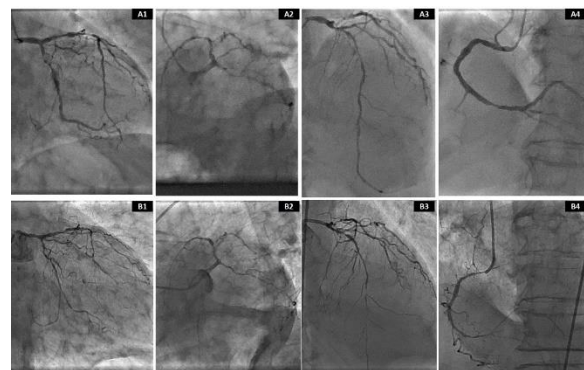


Figure 1: Angiography one month before showing severe disease in proximal LCx, LAD, and RCA (A1-A4), presenting angiography showing diffused multi-vessel coronary artery spasm involving LM, LAD, LCx, and RCA (B1-B4)

He was nonalcoholic but an Ex-smoker and left smoking 10 years ago, his weight was 65 kg with a BMI of 21. On Examination he was dyspneic with

spo2 of 85%, blood pressure was 70/40, pulse 120 beats/min. After oxygen support his ECG was performed which shows ST elevation in inferior leads, he was diagnosed as Inferior wall ST elevation Myocardial infarction (IWSTEMI) with Killip class IV (Figure 2). Patient was started on treatment with Aspirin 300 mg stat, Clopidogrel 600 mg stat and inj heparin 5000 IU and Norepinephrine 30 mics/kg because of cardiogenic shock he was intubated and put on ventilator as his ABGS was Ph:7.25, PaO2:55 mmhg PaCO2: 20 mmhg, HCO3:14mmol/l.

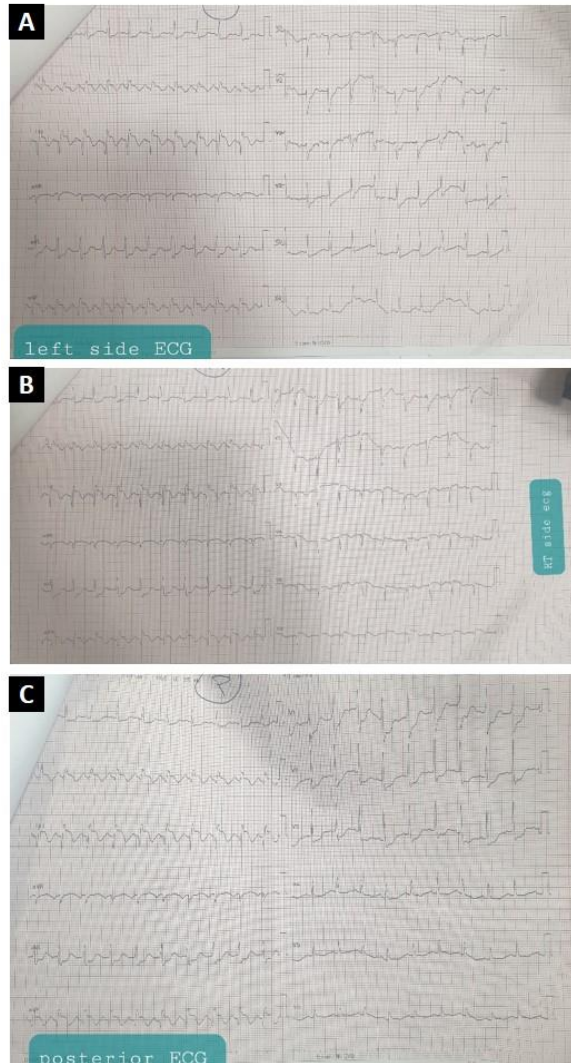


Figure 2: Left sided (A), Right (B), and Posterior (C) ECG at presentation

After initial management patient was shifted to Cath Lab for primary PCI, right femoral access taken his end diastolic pressure EDP 30mmhg. From Left femoral access intra-aortic balloon pump was inserted for countering hemodynamics compromise. Angiography was performed which showed diffuse spasm of LM, LAD, LCX, and RCA was diffusely

disease with critical tubular lesion in distal segment (Figure 1B). All three vessel look like threads as per previous angiography result it was diagnosed as diffuse multi-vessel spasm so consciously Intracoronary Nitrates of 100 mic given in spite patient was on norepinephrine support surprisingly after nitrates spasm was slowly relieving and patients hemodynamic were improving so up to 1000 mic nitrates given and spasm was relieved (Figure 3A) and blood pressure improve to 140/90 so support was stopped and distal RCA stented with DES onyx 3.5×18 (Figure 3B) and post dilated with 3.5×8 NC balloon good results achieved, later left system angiography repeated after giving intracoronary nitrates resulting spasm relieved (Figure 3D-E) procedure was completed and patient shifted to CCU.

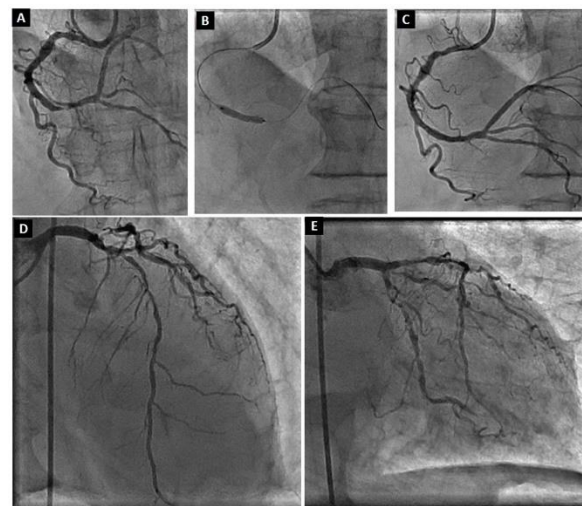


Figure 3: Angiographic results after intracoronary nitrates (A) PCI to distal RCA (B), final results (C), and repeated left system views after giving intracoronary nitrates (D-E)

DISCUSSION

Diagnosing coronary artery spasm (CAS) can be challenging as the clinical condition mimic other conditions and its different presentation. Sudden constriction of muscles within the arteries of the heart lead to narrowing of vessels and prevent blood flow mimicking myocardial infarction is known as CAS which can be brief and temporary in nature. Our case is among very few cases in which patient of malignant multi-vessel coronary artery spasm presenting as inferior wall myocardial infarction with cardiogenic shock showing response to intracoronary nitrates. Patient was diabetic, hypertensive and has history smoking which he left 10 years back. Our case report is consistent with the case report of Ozdemir D et al.⁴ in which patient presented with MI and arrhythmias and on angiography there was diffuse coronary

vasospasm, although the patient had previous history of arrhythmias for which he was receiving treatment.

Intracoronary nitroglycerin (ICN) should not be given to hemodynamically unstable patients, as our patient was in shock with norepinephrine support and dramatic response of ICN in relieve vasospasm and improvement of hemodynamics, it suggests that local response of ICN is more potent than the systemic response of norepinephrine, it is also consistent with case report of Thomson v et al.⁵

In summary, diagnosing CAS is really important but challenging to prevent complication like MI, arrhythmias and sudden cardiac death from occurring. At the same time we should also keep in mind Malignant multi-vessel coronary spasm as a cause if patient present with its rare complication as MI and shock.

This case report brings the importance of early diagnosis of coronary artery spasm to prevent the occurrence of MI, arrhythmias and sudden cardiac death as it is one the rare cause of them and should also be suspected despite known cardiac disease. It also highlighted the role of intracoronary nitroglycerine in relieving diffuse multi-vessel vasospasm in hemodynamically unstable patient.

Address for Correspondence:

Dr. Jehangir Ali Shah, Assistant Professor at National Institute of Cardiovascular Diseases (NICVD), Rafiqi (H.J.) Shaheed Road, Karachi- 75510, Pakistan.

Email: dr_shah_80@hotmail.com

AUTHORS' CONTRIBUTION

ASM: Concept and design, data acquisition, interpretation, drafting, final approval, and agree to be accountable for all aspects of the work. HS, NQ: Data acquisition, interpretation, drafting, final approval and agree to be accountable for all aspects of the work.

Conflict of interest: Authors declared no conflict of interest.

REFERENCES

1. Slavich M, Patel R. Coronary artery spasm: Current knowledge and residual uncertainties. *Int J Cardiol Heart Vasc.* 2016;10:47-53.
2. Picard F, Sayah N, Spagnoli V, Adjedj J, Varenne O. Vasospastic angina: a literature review of current evidence. *Arch Cardiovasc Dis.* 2019;112:44-55.
3. Rodríguez-Mañero M, Oloriz T, Le Polain De Waroux JB, Burri H, Kreidieh B, et al. Long-term prognosis of patients with life-threatening ventricular arrhythmias induced by coronary artery spasm. *Ep Europace.* 2018;20(5):851-8.
4. Ozdemir D, Kishor J, Hall JM, Chadow H, Rafii SE. A Rare Case of Vasospastic Angina Presenting with Inferior Lead ST-segment Elevation and Ventricular Fibrillation in the Absence of Coronary Obstruction: A Case Report. *Cureus.* 2019;11(12);e6332.
5. Thomson VS, Tariq O, Al Hadhi H. Malignant multivessel coronary spasm complicated by myocardial infarction, transient complete heart block, ventricular fibrillation, cardiogenic shock and ischemic stroke. *Oman Med J.* 2014;29(4):296.