

## CASE REPORT

## TREMORS MIMICKING ATRIAL FLUTTER IN AN ELDERLY LADY

Intisar Ahmed<sup>1</sup>, Hunaina Shahab<sup>2</sup>, Aamir Hameed Khan<sup>1</sup><sup>1</sup>Aga Khan University Karachi, Pakistan, <sup>2</sup>Icahn School of Medicine at Mount Sinai, New York

A 77-year-old lady with history of hypertension and Parkinson's disease was admitted with cough and fever and diagnosed as pneumonia. On second day of admission, she started having chest pain, initial ECG was interpreted as atrial flutter. When her ECG was reviewed by a cardiologist, ECG features were found to be consistent with artifacts due to tremors. A repeat 12 leads ECG clearly demonstrated normal sinus rhythm and the patient remained completely asymptomatic throughout the hospital stay. Tremor induced artifacts can be mistaken for arrhythmias. Correct diagnosis is important, in order to avoid inappropriate treatment and unnecessary interventions.

**Keywords:** tremors, atrial flutter, Parkinson's disease

**Citation:** Ahmed I, Shahab H, Khan AH. Tremors Mimicking Atrial Flutter in an Elderly Lady. Pak Heart J. 2021;54(04):370-372. DOI: <https://doi.org/10.47144/phj.v54i4.2120>

## INTRODUCTION

Parkinson's disease is one of the most common degenerative neurological diseases, characterized by the loss of nerve cells in parts of brain which controls movements and balance. Substantia nigra is the mainly involved area, which contains neurons using dopamine as a primary neurotransmitter.<sup>1</sup> Its incidence increases with age and up to 2% of the population above the age of 65 years develop Parkinson's disease. Parkinson's disease is characterized by slowness in movement (bradykinesia), increased muscle tone (rigidity), loss of posture, gait impairment, as well as resting tremors.

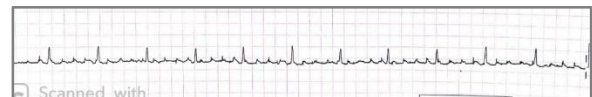
Typical atrial flutter is a reentrant supraventricular tachycardia which involves cavo-tricuspid isthmus as a part of reentry circuit. On a surface electrocardiogram (ECG), it is characterized by an atrial rate of approximately 300 beats/minute with typical saw-tooth appearance of flutter waves.<sup>2</sup> Patients with atrial flutter present with palpitations, fatigue, dizziness and sometimes transient ischemic attacks or stroke. Atrial flutter can also lead to tachycardia induced cardiomyopathy, and heart failure, especially in patients with uncontrolled ventricular rate.<sup>3</sup> Cerebrovascular and other systemic embolic risk in atrial flutter is equal to that in patients with atrial fibrillation.<sup>3</sup>

A 12 leads ECG is the major tool for the diagnosis of atrial flutter as well as other supraventricular and ventricular arrhythmias. Electrocardiographic artifact has been reported in literature as a common finding in surface ECG, especially when ECG leads are not in firm contact with skin.<sup>4</sup> It is essential to differentiate artifacts from true arrhythmias. This helps in preventing an unnecessary intervention in the form of antiarrhythmic medications, anticoagulation and even

electrical cardioversion. Tremors in patients with Parkinson's disease are one of the most common ECG artifacts, which may resemble atrial flutter. We present a case of Parkinson's disease in which tremors mimicked atrial flutter and will discuss relevant literature.

## CASE REPORT

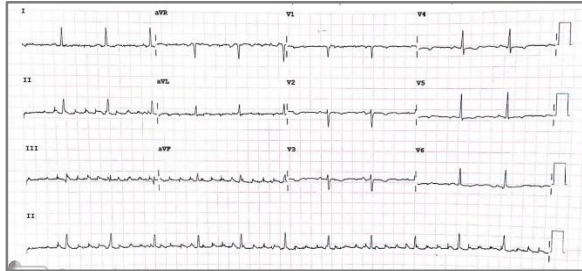A 77-year-old lady with hypertension and Parkinson's disease, presented to an emergency department with 2 days history of fever and nonproductive cough. She denied chest pain, shortness of breath, palpitations or syncope. Her home medications included carbidopa-levodopa, amlodipine, and esomeprazole. On initial examination, she was found to have a heart rate of 96/minute, her blood pressure was 100/70 mmHg; her respiratory rate was 18/minute and she had a temperature of 37°C. Chest examination revealed signs of consolidation in the right lower lung zone. Neurological exam showed bilateral resting tremors and rigidity, especially in both the upper limbs. Her initial laboratory investigations included hemoglobin of 11.9g/dl, total leukocyte count 9400/micL, serum sodium of 135 mmol/L, and serum potassium of 3.9mmol/L. Her serum creatinine was 0.8mg/dl, magnesium was 2.1mg/dl, and pro-brain natriuretic peptide (pro-BNP) was 19. Her x-ray chest demonstrated right lower lung zone alveolar infiltrates with air bronchogram.



**Figure 1: Rhythm lead showing Flutter waves**

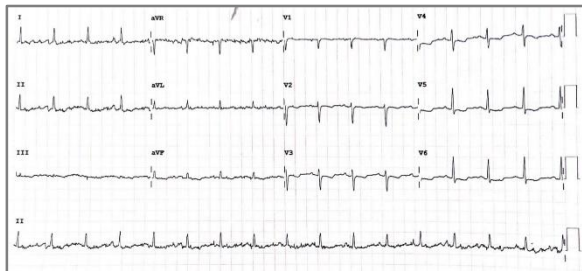She was admitted and started on intravenous antibiotics along with intravenous hydration and antipyretics as needed. On the second day of

hospitalization, she started having right-sided pleuritic chest pain. Cardiac monitor and rhythm strip suggested rhythm abnormality (Figure 1). Initial 12 lead ECG was interpreted as atrial flutter by the primary physician. (Figure 2).



**Figure 2: Initial ECG shows prominent “pseudo flutter” waves in inferior leads**

After a careful review of the ECG by a cardiology resident, she was found to have sinus rhythm with artifacts, due to sharply contoured p waves and more prominent artifacts in the limb leads compared to the chest leads. A repeat 12 lead ECG (shown in Figure 3) was done after immobilizing her limbs, which showed sinus rhythm with very few artifacts.



**Figure 3: Repeat ECG, showing clear sinus p waves**

## DISCUSSION

Artifacts on a surface electrocardiograms are common in a hospital setting. These artifacts may mimic supraventricular and ventricular arrhythmias leading to inappropriate treatment which can lead to a harm in the form of side effects of antiarrhythmic drugs and even electrical cardioversion.<sup>5</sup> In our case, a false diagnosis of atrial flutter could have led to the lifelong anticoagulation as she had a high risk of stroke (CHA2DS2-VASc score of 4).

Tremors related ECG artifacts have been reported in the literature. In a study by Hwang et al, ECG artifacts were found in more than 70% of the patients with tremors and in 10% of the patients those artifacts mimicked supraventricular or ventricular arrhythmias.<sup>6</sup> This study further revealed that, misinterpretation of ECG artifacts is much more common in internists and neurology postgraduate

residents as compared to cardiology postgraduate doctors, which indicates the importance of consultation with the specialists to reduce the potential complications.<sup>6</sup>

In order to differentiate the ECG artifacts from arrhythmias, patients' history, clinical examination and different electrocardiographic characteristics should be observed. While recording a 12 lead ECGs, it is mandatory to reduce the environmental sources of artifacts including tremors, patient's movement as well as electromagnetic interference.<sup>7</sup> Parkinson's tremors have a frequency of 250-350/minute, which is in the range of atrial flutter rate. However, there is an isoelectric baseline between these pseudo flutter waves and these waves do not have consistent morphology, as shown in our case. ECG characteristics which differentiate artifacts from atrial flutter may include, sudden onset and abrupt termination without symptoms, presence of discernible sinus P waves marching through the artifacts, unusual P wave morphology with sharp contours and more prominent flutter waves in limb leads as compared to chest lead. In a patient with suspected artifacts mimicking ventricular tachyarrhythmias, absence of symptoms and presence of hemodynamic stability supports the artifacts.

As the Parkinsonian tremors are more commonly present in the hands, feet and face, so, the artifacts are more prominent in the limb leads as compared to the precordial leads.

Patients with Parkinson's disease are at an increased risk of fall due to postural instability. Inappropriate and undue anticoagulants, put them at a risk of intracranial bleed leading to increased mortality and morbidity.<sup>8</sup> False diagnosis of atrial flutter may lead to inappropriate hospital admissions and clinical visits, which contribute towards an unnecessary health care cost burden.

In conclusion, this case report highlights the importance of electrocardiographic features, which help in differentiating tremor induced artifacts from a true arrhythmia. Accurate diagnosis of an ECG artifact requires careful interpretation by an expert, in the context of history and clinical examination. This is mandatory in order to prevent the inappropriate treatment and undue intervention.

## AUTHORS' CONTRIBUTION

IA: Concept and design, data acquisition, interpretation, drafting, final approval, and agree to be accountable for all aspects of the work. HS, AHK: Data acquisition,

interpretation, drafting, final approval and agree to be accountable for all aspects of the work.

**Conflict of interest:** Authors declared no conflict of interest.

## REFERENCES

1. Kalia LV, Lang AE. Parkinson disease in 2015: Evolving basic, pathological and clinical concepts in PD. *Nat Rev Neurol*. 2016;12(2):65-6.
2. Granada J, Uribe W, Chyou PH, Maassen K, Vierkant R, Smith PN, et al. Incidence and predictors of atrial flutter in the general population. *J Am Coll Cardiol*. 2000;36(7):2242-6.
3. Seidl K, Hauer B, Schwick NG, Zellner D, Zahn R, Senges J. Risk of thromboembolic events in patients with atrial flutter. *Am J Cardiol*. 1998;82(5):580-3.
4. Rudiger A, Hellermann JP, Mukherjee R, Follath F, Turina J. Electrocardiographic artifacts due to electrode misplacement and their frequency in different clinical settings. *Am J Emerg Med*. 2007;25(2):174-8.
5. Baranchuk A, Shaw C, Alanazi H, Campbell D, Bally K, Redfeam DP, et al. Electrocardiography pitfalls and artifacts: the 10 commandments. *Crit Care Nurse*. 2009;29(1):67-73.
6. Hwang WJ, Chen JY, Sung PS, Lee JC. Parkinsonian tremor-induced electrocardiographic artifacts mimicking atrial flutter/fibrillation or ventricular tachycardia. *Int J Cardiol*. 2014;173(3):597-600.
7. Van Mieghem C, Sabbe M, Knockaert D. The clinical value of the ECG in noncardiac conditions. *Chest*. 2004;125(4):1561-76.
8. Wood BH, Bilclough JA, Bowron A, Walker RW. Incidence and prediction of falls in Parkinson's disease: a prospective multidisciplinary study. *J Neurol Neurosurg Psychiatry*. 2002;72(6):721-5.

## Address for Correspondence:

**Dr. Aamir Hameed Khan**, Professor of Medicine and Consultant Cardiologist, Aga Khan University, Stadium Road, Karachi, Pakistan.

**Email:** [aamir.hameed@aku.edu](mailto:aamir.hameed@aku.edu)