

LEARNING CORNER**SECTION EDITOR****Fathe Ali Tipoo Sultan**Aga Khan University Hospital, Karachi,
Pakistan

Dr. Tipoo is currently working as Associate Professor and Consultant Cardiologist at Aga Khan University Hospital, Karachi. Dr. Tipoo has 46 publications in Indexed National and International Journals and is the author of a book on Echocardiography.

ECHOGENIC MASS ATTACHED TO TRICUSPID VALVE**Imran Hameed¹**¹Anklesaria Nursing Home, Karachi, Pakistan**SUMMARY**

A 5-day old female child with complaints of tachypnea, had TTE which revealed an echogenic mass on septal leaflet of Tricuspid valve. Based on echocardiographic features, it was diagnosed as Papillary fibroelastoma.

CASE DESCRIPTION

A 5-day old female child was referred for transthoracic echocardiographic study due to respiratory difficulty. The child was afebrile and had a respiratory rate of 60/min, heart rate 130 bpm, and blood pressure 80/50 mmHg. No murmur or added sound heard on CVS examination. TTE revealed a dense mass (Figure 1) attached to right atrial side of septal leaflet of Tricuspid valve by a small pedicle. The mass was mobile, prolapsing into right ventricle during diastole (Clips) without causing obstruction with size of 0.8 X 0.74 cm. Intracardiac masses attached to valves are usually Papillary fibroelastomas. Other possible differential diagnoses could be myxoma, vegetation, Lambl's excrescence or secondary tumors etc. Based on the location and echo features of the mass (mobility, attachment to downstream side of valve, and frond like speckled appearance) the diagnosis of Papillary fibroelastoma was made.

LEARNING POINTS

1. Cardiac tumors are rare and mostly benign.
2. The three most common primary tumors of heart, in order of frequency, are myxomas, lipomas and papillary fibroelastomas respectively. PFE constitute 7% - 9% of all.¹
3. PFE usually arise from valves of the heart and are mostly left-sided.²
4. They are mobile, range from 0.5 – 2 cm in size and have a frond-like appearance. On echo, they are dense with a speckled interior and shimmering surface.³
5. Being prone to embolization and thrombosis, their clinical course may not be benign, especially left sided.

CLIPS

- Subcostal Clip: https://youtu.be/_xTZmx--WcA
- PS SAX View: <https://youtu.be/ILh6D9Vn4Fw>
- A4C View: https://youtu.be/_xZZvTIh0S8
- A4C RV Directed View: <https://youtu.be/vJRyHrevftA>

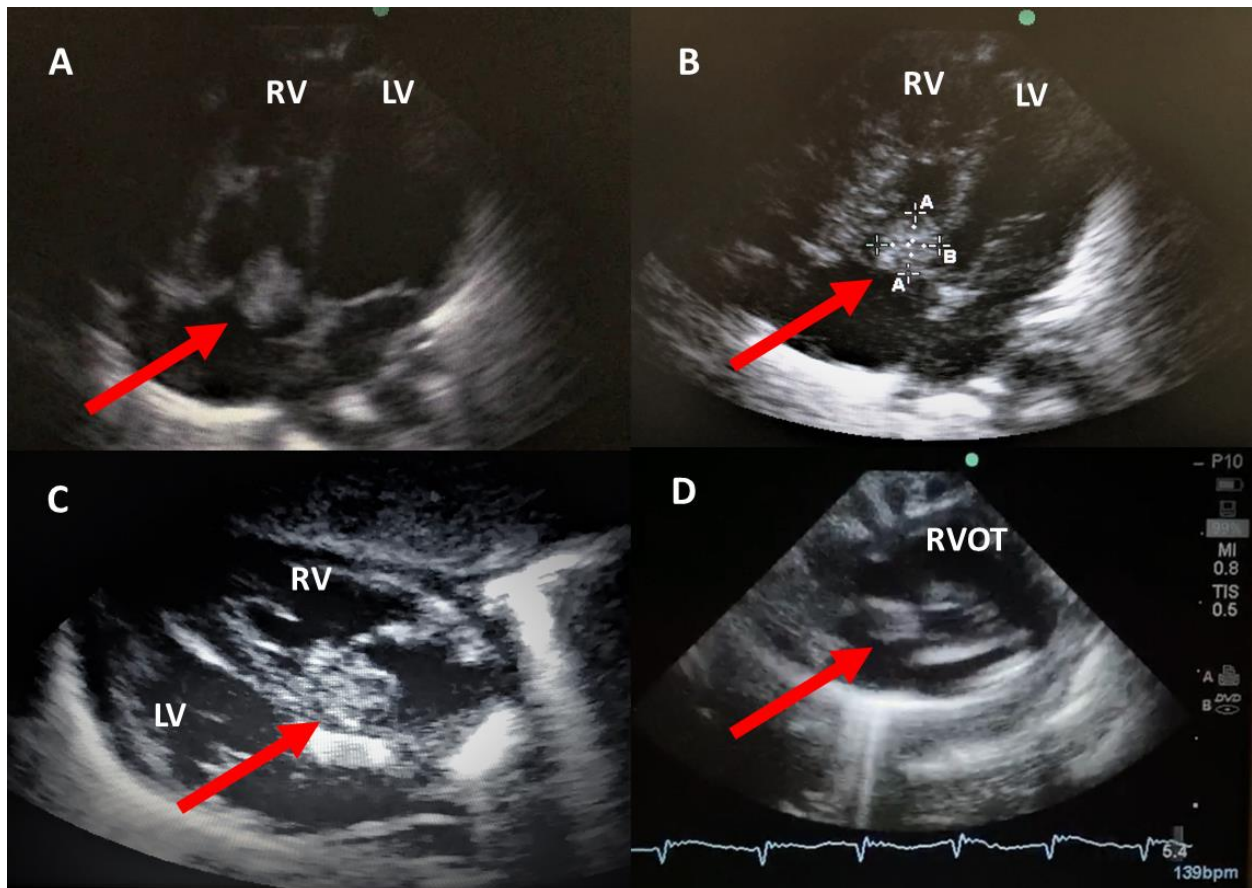


Figure 1: Echogenic mass attached to septal leaflet of Tricuspid valve (shown by red arrow). Panel A and B A4C views, Panel C Sub-costal view and Panel D PS SAX view at Pulmonary artery level

QUESTIONS WITH ANSWERS

- **Question 1:** What is the most common complication of papillary fibroelastoma?
- **Question 2:** The behavior of right and left sided papillary fibroelastomas could be markedly different, Y/N?
- **Question 3:** What is the most important feature of papillary fibroelastoma for embolization?
- **Question 4:** PFE preferentially affects females, Y/N?

Answers

- **Question 1:** Cerebral embolism
- **Question 2:** Yes
- **Question 3:** Mobility
- **Question 4:** No

REFERENCES

1. Bouhzam N, Kurtz B, Doguet F, Eltchaninoff H, Bauer F. Incidental papillary fibroelastoma multimodal: imaging and surgical decisions in 2 patients. *Tex Heart Inst J.* 2012;39(5):731-5.
2. Eidem BW, Cetta F, O' Leary PW. *Echocardiography in pediatric and adult congenital heart disease.* Lippincott, Williams and Wilkins, Wolters Kluwer. 2010 p 355-361.
3. Klarich KW, Enriquez-Sarano M, Gura GM, Edwards WD, Tajik AJ, Seward JB. Papillary fibroelastoma: echocardiographic characteristics for diagnosis and pathologic correlation. *J Am Coll Cardiol.* 1997;30(3):784-90.

Citation: Hameed I. Echogenic Mass Attached to Tricuspid Valve. *Pak Heart J.* 2021;54(02):201-202. DOI: <https://doi.org/10.47144/phj.v54i2.2100>

Address for Correspondence:

Dr. Imran Hameed, Anklesaria Nursing Home, Aga Khan III road garden, Karachi, Pakistan.
Email: imranhameed61@hotmail.com