

CARDIAC MANIFESTATION WITH RARE PANCREATIC AGENESIS: A CASE REPORT WITH REVIEW OF LITERATURE

Iftekhhar Ahmed¹, Salma Salman¹, Tariq Farman¹

¹ Dow University of Health Sciences, Karachi, Pakistan

Address for Correspondence:

Salma Salman
Dow University of Health Sciences,
Karachi, Pakistan.

Email: salma_sheikh8@hotmail.com

Contribution

IA conceived the idea of the case report. Data collection and manuscript writing was done by IA, SS, TF. All the authors contributed equally to the submitted manuscript.

All authors declare no conflict of interest.

This article may be cited as: Ahmed I, Salman S, Farman T. Cardiac Manifestation with Rare Pancreatic Agenesis: A Case Report with Review of Literature. Pak Heart J 2021;54(01):120–123.

<https://doi.org/10.47144/phj.v54i1.2075>

ABSTRACT

Due to increasing radiology in current era more and more rare radiological manifestation are coming in front. We reported a rare case of pancreatic agenesis with cardiac manifestation documented echocardiographically which include pulmonary stenosis, and mild pulmonary arterial hypertension. Due to mutation in gene these changes are possible but due to cost constraint we are unable to document genetic mutation.

Keywords: pancreatic a genesis, echocardiographically, pulmonary stenosis, pulmonary arterial hypertension

INTRODUCTION

Pancreatic a-genesis in literature is a rare entity, and only few cases are associated with cardiac manifestation. Cardiac manifestation documented in different case reports are ventricular septal defect, tetralogy of fallot and pulmonary stenosis.¹ The earliest reported case of pancreatic a-genesis was noticed in 1911.¹ Genetic mutation in GATA 6 gene is thought to be the responsible factors of these combined abnormalities involving cardiac as well as pancreas.² During the embryonic phase of life the junction between foregut and midgut of septum transversum split up into two buds dorsal and ventral which later on unite to form the pancreas. The main portion of pancreas is form by dorsal bud and ventral bud. Both of these buds contribute in the development of head, uncinete process and bile duct portion. The ventral agenesis is not consistent with life. As far as dorsal agenesis is concerned, it is very rare and is only reported in case reports. The dorsal agenesis may be asymptomatic, but some time manifested as abdominal pain, diabetes mellitus and chronic pancreatitis.³

Clinical awareness of this rare condition is necessary for clear understanding of its association and possible complication so that timely management can be appreciated. As genetic link has been identified in this rare manifestation, genetic counselling should be part of treatment therapy.

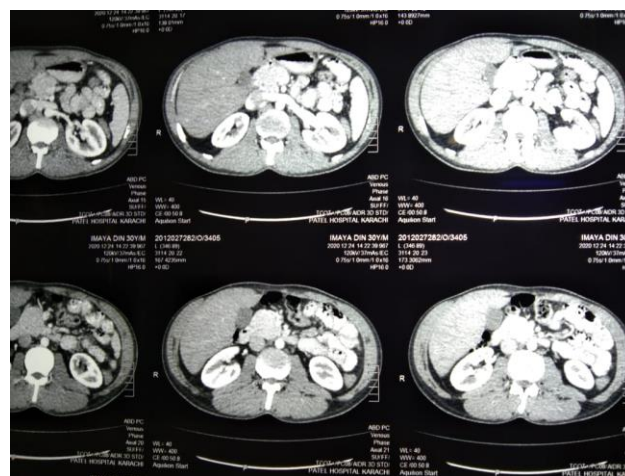
CASE REPORT

A 30 year old male resident of Afghanistan came to OPD of a private setup with presentation of abdominal pain for more than 10 year of mild intensity and shortness of breath for 2 month. The pain increases in intensity for the past 2 month, not associated with fever, vomiting or alteration in bowel habits. There were no exacerbating or relieving factors. Shortness of breath was present on moderate exertion. He denied orthopnea, paroxysmal dyspnea and any pedal swelling. He denied the history of alcohol and pan challia.

He noticed weight loss in past 1 year which was undocumented. There was no significant family history. No birth history was available. On examination young male of average height and built

(height 168 cm ,weight 68 kg ,BMI 24.2 Kg/m²,BSA 1.77m²) with no remarkable abnormality. There was grade 2 tenderness in epigastric region, on auscultation systolic murmur consistent with pulmonary stenosis was present, rest of the examination was unremarkable. Labs reveal normal CBC (Complete blood count), UCE (urea, creatinine and electrolyte), RBS (Random blood sugar), Urine DR is normal serum amylase and lipase were also within the normal range thus excluding any evidence of diabetes mellitus or chronic pancreatitis. Ultrasound revealed enlarge head of pancreas, CT scan abdomen showed enlarge head of pancreas with absence of pancreatic body and tail. There was no evidence of pancreatic duct dilatation .Overall appearance suggestive of pancreatic agenesis (Figure 1).

Figure 1: CT scan abdomen (showing enlarge head of pancreas and absent body and tail)

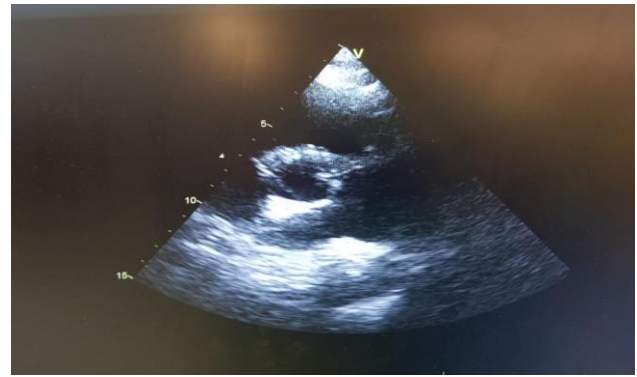
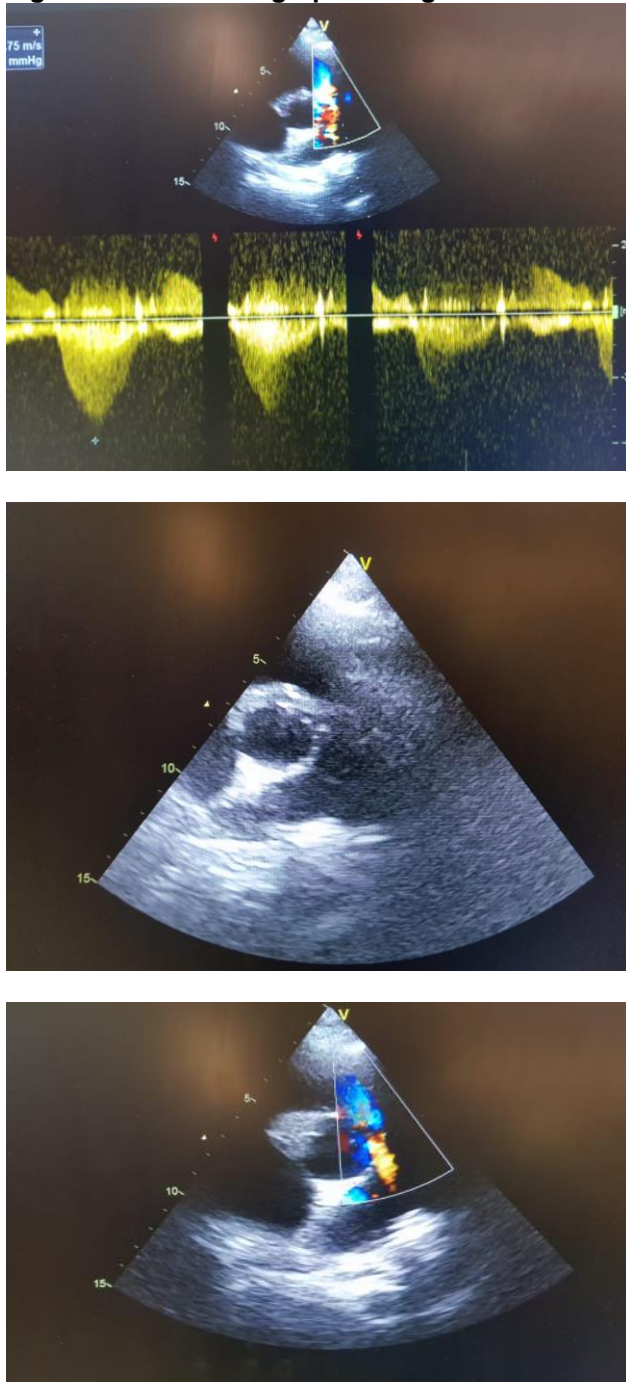


Echocardiography concludes normal size all cardiac chambers with preserved left ventricular systolic function. LVEF 55%. Grade 1 left ventricular diastolic dysfunction. Mild pulmonary artery hypertension and mild pulmonary stenosis. PPG 40 mmHg, MPG 23 mmHg. Hypertrophic right ventricular wall Normal Aortic valve, Images are shown in Figure 2.

After cardiology consultation, considering very mild symptoms, no further examination or investigations were performed. We recommend no specific therapy

for the patient, however, supportive care and counselling provided in detail. The patient was advised for follow up on OPD basis with suggestion to perform relevant blood test annually to monitor pancreatic function. Due to cost constraint we were unable to perform NGS panel to document genetic mutation.

Figure 2: Echocardiographic images



DISCUSSION

The dorsal pancreatic agenesis is not so prevalent condition and it is rarely found. Due to recent increase in advances of radiology, the cases are coming forward in noticed. In literature only few cases are reported up till now.⁴ In our scenario pancreatic agenesis wasn't expected and diagnosed radiologically through CAT scan of abdomen.

Pancreatic agenesis is also associated with congenital heart anomalies like septal defect, pulmonary artery stenosis and tetralogy of fallot.⁵ It is also associated with pancreatic malignancy as well, and some rare finding which include heterotaxy and polysplenia syndrome

Our case targeted to the group with associated cardiac manifestation, but luckily they were of mild nature. The exact pathology of these association is unknown however the possibility of genetic mutation and development of pancreas in close proximity of these structure should be considered.⁶

Through review of literature also revealed that there were wide range of presentation of pancreatic ageneis as far as symptomatology is concerned, many cases are asymptomatic. Few present with abdominal pain, some with hyperglycemia and pancreatitis. Among these abdominal pain is the frequent symptom.³ Our case presented with mild abdominal pain. However, investigations reveal normal amylase and lipase excluding pancreatitis. The inflammatory markers were also within the normal range. The pain may be because of compensatory hypertrophy of the remaining part, hyper secretion of enzyme from rest of the portion and higher ductal pressure.³

In conclusion, cardiac manifestation with pancreatic agenesis is a rare finding. Subjects with pancreatic agenesis should be investigated for other rare co-

morbid conditions, and should be kept on follow up for the monitoring of symptoms so that timely management can be started.

REFERENCES

1. Mohapatra M, Mishra S, Dalai PC, Acharya SD, Nahak B, Ibrarullah M, et al. Imaging findings in agenesis of the dorsal pancreas. Report of three cases. *JOP*. 2012;13(1):108-14.
2. Chao CS, McKnight KD, Cox KL, Chang AL, Kim SK, Feldman BJ. Novel GATA6 mutations in patients with pancreatic agenesis and congenital heart malformations. *PLoS One*. 2015;10(2):e0118449.
3. Uygur-Bayramiçli O, Dabak R, Kiliçoğlu G, Dolapçioğlu C, Oztas D. Dorsal pancreatic agenesis. *JOP*. 2007;8(4):450
4. Valiyeva S, Romano L, Schietroma M, Carlei F, Giuliani A. Partial agenesis of dorsal pancreas. Report of two cases. *Int J Surg Case Rep*. 2020;77S:S17-S20.
5. Shimodaira M, Kumagai N, Sorimachi E, Hara M, Honda K. Agenesis of the dorsal pancreas: A rare cause of diabetes. *Intern Emerg Med*. 2012;7:83–4.
6. Thakur S, Jhobta A, Sharma D, Thakur CS. MR in complete dorsal pancreatic agenesis: Case report and review of literature. *Indian J Radiol Imaging*. 2014;24(2):156-9.