

## LEFT ATRIUM THROMBUS ASSOCIATED WITH VENO-ARTERIAL EXTRACORPOREAL MEMBRANE OXYGENATION (VA-ECMO)

Hassan H Allam<sup>1</sup>, Abdulhalim Jamal Kinsara<sup>2</sup>, Fawaz Altaf<sup>1</sup>, Amt Alkhaliq A Alrajawi<sup>1</sup>, Tareq Tuiama<sup>1</sup>, Shadwan E Alfakih<sup>1</sup>

1 King Abdullah Medical Complex, Jeddah, Ministry of Health, Jeddah, Saudi Arabia.

2 Ministry of National Guard-Health Affairs, King Saud Bin Abdulaziz University for Health Sciences, COM-WR, King Abdullah International Medical Research Center, Jeddah, Saudi Arabia.

### Address for Correspondence:

Dr. Abdulhalim Jamal Kinsara  
Department of Cardiology, Ministry of National Guard-Health Affairs, King Saud Bin Abdulaziz University for Health Sciences, COM-WR, King Abdullah International Medical Research Center, Jeddah, Saudi Arabia.

Email: akinsara@yahoo.com

### Contribution

HHA conceived the idea of the case report. Data collection and manuscript writing was done by HHA, AJK, FA, AAAA, TT, and SEA. All the authors contributed equally to the submitted manuscript.

All authors declare no conflict of interest.

**This article may be cited as:** Allam HH, Kinsara AJ, Altaf F, Alrajawi AAA, Tuiama T, Alfakih SE. Left atrium thrombus associated with Veno-arterial Extracorporeal Membrane Oxygenation (VA-ECMO). Pak Heart J 2020;53(03):279-282.

<https://doi.org/10.47144/phj.v53i3.1948>

### ABSTRACT

Extra corporeal membrane oxygenation, specifically the veno-arterial type (VA-ECMO) is an effective cardiac support device but has potential negative effects, such as poor myocardial rest, increased after load with subsequent pulmonary edema or decreased flow to the left side of the heart resulting in intra-cardiac thrombus formation. Hence, adequate left ventricular drainage and adequate anticoagulation are essential. We are presenting a patient who required central VA-ECMO, but developed a left atrial (LA) thrombus, which adversely affected his outcome.

In VA-ECMO, thrombus formation in the left side of the heart is a potential harmful complication.

Early recognition is an important step to arrange appropriate interventions, either early anticoagulation or the potential need for a LV vent to prevent stasis.

**Keywords:** Extra corporeal membrane oxygenation, left atrium thrombus, cardiogenic shock.

## INTRODUCTION

Ventricular dysfunction may present as a simple heart failure or result in cardiogenic shock. To treat the acute circulatory failure, the extracorporeal membrane oxygenation (ECMO) had raised as a bridge to ultimate therapy.<sup>1</sup> The veno-arterial (VA)-ECMO technique is easy to implant and deliver optimal cardiac and respiratory support.<sup>2</sup> However, complications are not rare with ECMO and reported as 40% in one series.<sup>3</sup>

Here we are reporting a rare complication, in the form of left atrium stasis and thrombosis (LA), which developed in a patient who commenced with ECMO to treat cardiogenic shock.

## CASE REPORT

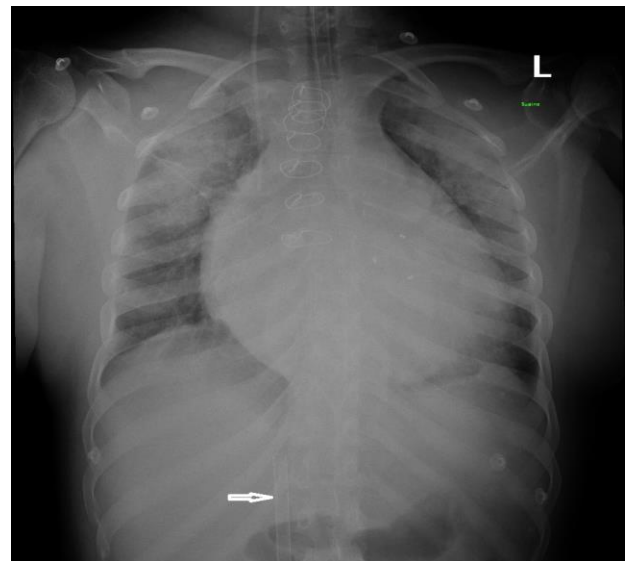
A female patient, aged 22 years, had acute onset dizziness. She had a history of a bio-prosthetic mitral valve replacement 10 years ago, due to a rheumatic condition. She is a known epilepsy patient with mild mental retardation and lives in a remote area with no regular follow-up. On examination she was conscious, looked ill, pale, jaundiced and her skin was cold and clammy. Her blood pressure was 68/31 mmHg and the heartrate 115 beats per min and irregular. There was a mid-line sternum scar of the previous cardiac surgery. There was a systolic murmur on the precordium and scattered crepitation in the lungs. The patient was diagnosed as in cardiogenic shock secondary to bioprosthesis dysfunction and started on a norepinephrine infusion and mechanical ventilation. The ECG showed atrial fibrillation and multiple PVCs. The initial laboratory results are summarized in Table 1.

**Table 1: Blood tests**

Test	Value	Reference
Haemoglobin	8.4 g/dL	12.0 - 15.0
Platelet Count	111 10 <sup>9</sup> /L	150 - 450
WBC	15.4 10 <sup>9</sup> /L	4.0 - 10.0
INR	2.1	0.9 - 1.2
Creatinine	1.7 mg/dL	0.7 to 1.2 mg/dL
PH	7.0	7.4
Bicarb	7.8	29

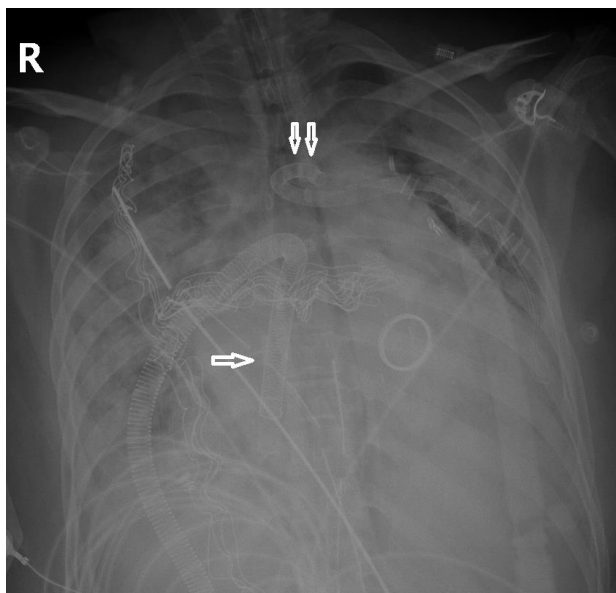
The bed side Echo indicated a dilated LV with severe systolic dysfunction, EF~ 30%, degenerated MV bio-prosthesis with severe mitral regurgitation combined with mitral stenosis (mean gradient 20 mmHg), a hugely dilated left atrium and severe pulmonary hypertension. The patient remained hypotensive with severe metabolic acidosis and was started on Dopamine and a Milrinone infusion without a significant improvement in hemodynamics. The team decided to insert a peripheral VA-ECMO (Figure 1).

**Figure 1: X-ray showing venous cannula of peripheral VA-ECMO**



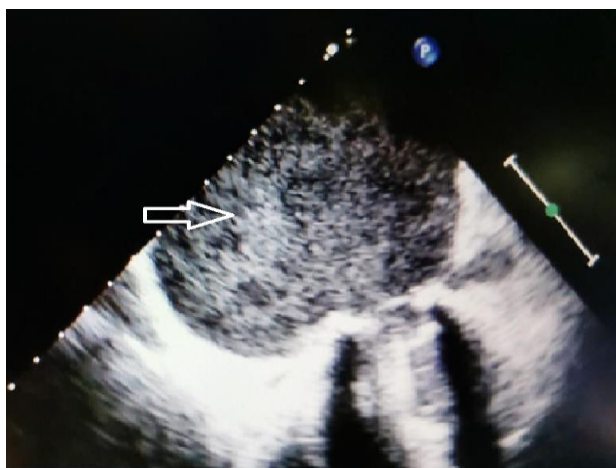
On Day 2 of admission, the patient developed signs of lower limb ischemia, and was taken to the operative room for the removal of the peripheral VA-ECMO and a mitral valve replacement was done. Due to difficult weaning from the bypass machine, a central VA-ECMO was inserted (Figure 2), the chest was packed and kept open. Due to post-operative bleeding and a right femoral hematoma, no anticoagulation was started.

**Figure 2: X-ray showing central VA-ECMO (one arrow the RA cannula, two arrows the aortic cannula)**

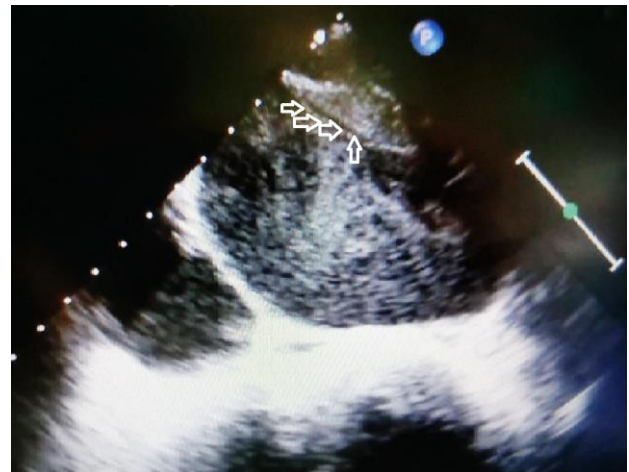

Three days later, the patient was taken to the OR again for the removal of the central VA-ECMO and closure of the sternum. An intraoperative TEE revealed a heavy LA contrast with big LA clot (Figure 3 A&B). Anticoagulation was started immediately. The postoperative period was extended, but uneventful. The patient was seen at follow-up at one, three and six months in the outpatient clinic and was uneventful.

**Figure 3: Heavy contrast in left atrium (arrow)**



**Figure 4: B. Large clot in left atrium roof (arrows)**



## DISCUSSION

Because of the poorly contracting, non-ejecting left ventricle (LV) or atrium, intracardiac thrombi may develop due to the decreased blood flow to the LV, increased afterload from the arterial cannula, and LV distention with resultant stasis.<sup>4</sup> Only a few cases of LA thrombosis and left ventricular thrombus formation due to stasis has been reported.<sup>5,6</sup> High ECMO circuit flow may protect against the development of thrombi inside the ECMO circuit, but not the left side of the heart. The patient should be maintained on inotropic support to maintain LV contractibility and a LV vent should be considered. Anticoagulation should be resumed as early as possible to avoid the risk of an intracardiac thrombus.

In conclusion, the low flow status inside the left side of heart during VA-ECMO may play the most crucial role in LA thrombus formation. Inotropic support and a LV vent should be considered to decrease the left side of heart stasis and thrombus formation. Adequate anticoagulation should be initiated as soon as possible after bleeding issues were corrected.

## REFERENCES

1. Hajjar LA, Teboul JL. Mechanical Circulatory Support Devices for Cardiogenic Shock: State of the Art. *Crit Care*. 2019;23:76.
2. Combes A, Leprince P, Luyt CE, Bonnet N, Trouillet JL, Pavie A, et al. Outcomes and long-term quality-of-life of patients supported by

- extracorporeal membrane oxygenation for refractory cardiogenic shock. *Crit Care Med.* 2008;36:1404-11.
3. Muller G, Flecher E, Lebreton G, Luyt CE, Trouillet JL, Bréchet N, et al. The ENCOURAGE mortality risk score and analysis of long-term outcomes after VA-ECMO for acute myocardial infarction with cardiogenic shock. *Intensive Care Med.* 2016;42(3):370-8.
  4. Weis F, Beiras-Fernandez A, Bruegger D. Huge intracardiac thrombosis in a patient on veno-arterial extracorporeal membrane oxygenation support. *Interact Cardiovasc Thorac Surg.* 2009;8:247-9.
  5. Lin PF, Chiu KM, Huang JH, Chen JS, Chu SH. Acute total left atrial thrombosis after mitral bioprosthesis replacement during ECMO support. *Heart Lung Circ.* 2015;24:e37.
  6. Makdisi G, Hashmi ZA, Wozniak TC, Wang IW. Left ventricular thrombus associated with arteriovenous extra corporeal membrane oxygenation. *J Thorac Dis.* 2015;7(11):E552-4.