

# Experience Of Permanent Pacemaker Implantation At NICVD

OWAIMA HASSAN\*

KHAN SHAH ZAMAN\*\*

## Summary:

Our study group compared 252 new patients who had permanent pacemakers implanted in the year 1994. Commonest presenting symptom was syncope found in 34.1% of patients, followed by vertigo in 30.1%. The most common ECG findings were complete heart block with atrioventricular asynchrony, seen in 71.4% followed by Mobitz Type II block in 10.3% and sick sinus syndrome in 7.9%. Mostly VVI type of PPMs were implanted and other more sophisticated type were used rarely.

## Aim of Study:

In this retrospective study we focused on the common presenting features and ECG findings of patients who required permanent pacemakers. The ages of patients, site of implantation and types of PPMs used and complications of the procedure were also reviewed.

## Inclusion Criteria:

We included patients of all ages and both sexes who had PPM implanted for the first time.

## Results:

Of the 252 patients 140 (55.55%) were males and 112(44.45%) were females, with ages varying from 10 yrs. to 94 yrs. The bulk of patients were in 50-70 years age group, 86(34.1%) of the patients presented with syncope, 76 (30.1%) with vertigo and 34 (13.4%) with chest pain.

## Presenting Symptoms:

S. No.	Symptoms	No. of Pts.	Percentage
01	Syncope	86	34.1 %
02	Vertigo	76	30.1 %
03	Chest Pain	34	13.4 %

04	Shortness of breath	27	10.7 %
05	Palpitations	16	06.30 %
06	Less common symptoms like sweating, nausea seizures. T.I.A's.		04.00 %

The common ECG findings were complete heart block in 180 (71.4%) of patients, Mobitz Type II AV block in 26 (10.3%) and Sinus node disease in 20 (7.3%) of patients.

## ECG Findings:

S. No.	ECG findings	No. of patients	Percentage
01.	Complete heart block	180	71.4%
02.	Mobitz Type II block	26	10.3%
03.	Sick Sinus Syndrome	20	7.9%
04.	Symptomatic Sinus brady Cardia.	8	3.2%

In 63.5% of patients the lead was implanted via the left cephalic vein in 35.5% through the subclavian vein and in 1.0% through the Jugular Vein, the left side being preferable. Of the early complications, i.e., those which occurred during the hospital stay of the patient, haematoma formation was observed in 12 of the patients. In only two of these patients was the wound reopened and the clots evacuated. Infection occurred in 4 patients and was promptly treated by antibiotics. Failure to capture was mainly due to lead dislodgement and was corrected by lead repositioning. The exact incidence of late complications could not be re-

\* Associate Professor, NICVD, Karachi.

\*\* Associate Professor, NICVD, Karachi.

liably assessed owing to erratic patient turn up in pacemaker clinics.

We used the VVI multiprogrammable PPMs in 94% of patients. In these PPMs the rate strength and duration of current can be adjusted non-invasively. In 5% of patients VVIR PPMs were used which exhibit rate adaptivity with exercise. In only 1% of patients pure atrial lead was used which was positioned in the Rt. atrial appendage.

### Discussion:

Each year in our institute we implant between 250-300 new permanent pacemakers besides this patients are admitted for lead repositioning and for change of pulse generators.

The number of PPMs being implanted annually has increased significantly over the past years. A previous study carried out in past showed the number of PPMs being implanted over a three years period to be 76 only.

The above mentioned data indicate that complete heart block remains by far the most common indication for PPMs implantation, in contrast to the Western countries where sinus node disease accounts for 40% of all implantations.

Although these patients present with diverse complaints, but a sizable proportion of patients with CHB/bradyarrhythmias present with classical syncope, therefore, the clinicians should maintain a high index of suspicion for these arrhythmias in patients with syncope. Important conditions to exclude are epilepsy in which there are tonic-clonic seizures, 'tongue biting' and incontinence, postural hypotension esp. in patients on antihypertensives, and vertebrobasilary T.I.As which are precipitated by neck movement. In contrast, syncope associated with conduction disturbance can occur at rest, is associated with pallor and is followed by extreme flushing. In transient rhythm disturbance on-the-spot ECGs are difficult to obtain therefore an eyewitness account of the attack could be quite helpful.

It is also mandatory to obtain a thorough drug history before making a decision to implant, as hypertensives and patients with ischaemic heart dis-

ease who are on beta blockers and/or calcium channel blockers may exhibit varying degrees of A.V. nodal blocks. These patients may merely require drug withdrawal and temporary pacing until they achieve sinus rhythm.

Some important approaches in the investigation of these patients are.

#### 1. Resting ECG:

This can be entirely normal in intermittent arrhythmias and may depict the rhythm disturbance in persistent ones.

#### 2. 24 Hrs. Holter Monitoring:

If a strong clinical suspicion exists and facilities are available then a continuous recording should be undertaken.

#### 3. Echocardiography:

This should be utilized for the assessment of left ventricular status. Even severe left ventricular dysfunction is not a contraindication for PPM implantation. A PPM may not correct the underlying cause but it will go a long way in achieving a definite improvement in the quality of the patients life.

#### 4. Exercise Tolerance Test:

This is used for the assessment of chronotropic reserve in patients who fail to show an increase in heart rate in response to an exercise challenge and become breathless, are strong candidates for PPM.

In fact, patients with a poor chronotropic reserve who were in refractory cardiac failure have been shown to improve markedly when the rate has been increased following PPM implantation.

An E.T.T. is also performed to unmask latent arrhythmias.

### Conclusion:

It is evident that this is an extremely safe procedure in experienced hands and the incidence of seri-

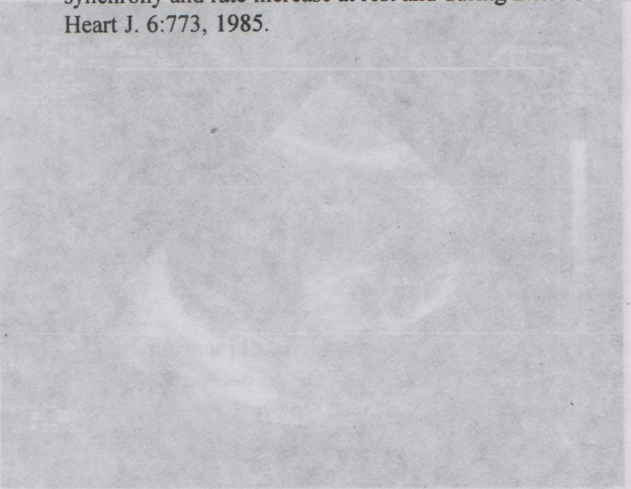
ous complications is very low, which compares favourably with our counterparts in more developed countries. But it is unfortunate that uptill now we have been unable to exploit it to maximum advantage. This is mainly because our economic considerations have shackled us into using this procedure for life saving purposes rather than for improving the quality of lives of patients. This is the main reason why we are still using cheaper single chamber VVI pacemakers where only the rate, duration and strength of current can be adjusted. We have implanted very few dual chamber devices (DDD) which have a greater flexibility of operation.

DDD pacemakers can prove invaluable in those with impaired LV function in whom the "atrial kick" or atrial contribution to ventricular filling could significantly increase the cardiac output in patients who present with the "pacemaker syndrome" in follow-up clinics also need an upgrading of their VVI systems to DDD ones. With the passage of time we hope to be able to utilize this procedure not merely as an emer-

gency measure but to extend its uses to restore near-normal haemodynamics during rest or exercise and also for the treatment of tachy arrhythmias using more sophisticated implantable devices which are capable of pacing, cardioversion and defibrillation.

**References:**

1. Indications for pacemaker insertion. Types and modes of pacing prog. Cardiovasc Dis. 23:393, 1981.
2. Permanent Ventricular Pacing: Effect of long term survival, Congestive Heart Failure and subsequent myocardial infection and stroke. Ann. Intern Med. 77:345,1972.
3. Pacemaker Syndrome: A noninvasive means to its diagnosis and treatment PACE 4:503'1981.
4. Atrial Versus Ventricular Pacing in sinus node disease. A treatment comparison study. Am Heart J. 111:292,1986.
5. The Haemodynamic so importance of atrioventricular synchrony and rate increase at rest and during Exercise Eur. Heart J. 6:773, 1985.



Transoesophageal Echocardiography Basic principles and applications. A Transoesophageal Echocardiogram (TTE) of the heart showing a small R1 AV connection, a small R1 outer chamber (picture 2), discordant AV connections, and a subvalvular Pulmonary stenosis having a peak instantaneous gradient of 70 mmHg. In addition, a pure aneurysm of the great septum (picture 3-5), arising from 2 cm of the atrial septum at Foramen Ovale level was seen. It was so big that it swung across freely from the left atrium into the LV inlet through the open mitral valve during ventricular diastole (pictures 4 and 5) and back into the LA in systole. Right to left shunting across this aneurysm could be seen on colour. A diagnosis of Tricuspid Atresia with discordant AV connections and P2, with aneurysm of the atrial septum was made.