

## ESTABLISHING INTERVENTIONAL TECHNOLOGIES TO TREAT UNDER EXPANDED STENTS: A ROLE FOR EXCIMER CORONARY LASER ATHERECTOMY

Vivek Kodoth<sup>1</sup>, Omar Rana<sup>2</sup>, Nalyaka Sambu<sup>3</sup>, Karim Ratib<sup>4</sup>, Paul Johnston<sup>5</sup>, Adrian Large<sup>6</sup>, Jim Nolan<sup>7</sup>, Adam deBelder<sup>8</sup>, Jehangir Din<sup>9</sup>, Suneel Talwar<sup>10</sup>, Peter O'Kane<sup>11</sup>

<sup>1,2,9-11</sup> The Royal Bournemouth Hospital, Bournemouth - UK

<sup>3,8</sup> The Brighton and Sussex University Hospital, Brighton - UK

<sup>4,7</sup> The University Hospital of North Staffordshire, Stoke-on-Trent - UK

<sup>5,6</sup> The Belfast Health and Social Care Trust, Belfast - UK

Address for Correspondence:

**Vivek Kodoth,**

Department of Cardiology, The Royal Bournemouth Hospital, Bournemouth - United Kingdom

Emails:vivekkodoth@btinternet.com

Date Received: April 07,2017

Date Revised: November 04,2017

Date Accepted: December 11,2017

### Contribution

VK,OR,NS and KR conceived the idea, planned the study and drafted the manuscript. PJ,AL,JN,AD,JD,ST & PK collected data, did statistical analysis, drafted the manuscript and critically reviewed manuscript. All authors contributed significantly to the submitted manuscript.

**All authors declare no conflict of interest.**

This article may be cited as: Kodoth V, Rana O, Sambu N, Ratib K, Johnston P, Large A, Nolan J, deBelder A, Din J, Talwar S, O'Kane P. Establishing interventional technologies to treat under expanded stents: A role for excimer coronary laser atherectomy. Pak Heart J 2018; 51 (01): 82-5

### ABSTRACT

**Objectives:** To evaluate the efficacy, safety, feasibility and medium term outcome of the use of excimer laser coronary atherectomy (ELCA) either alone or combined with rotational atherectomy (RA) for the management of under expanded stents.

**Methodology:** In this case series we collected the procedural details, images, equipment used, complications and follow up details of patients from June 2009 to October 2014, who had undergone ELCA PCI for under expanded stents in four high volume UK, PCI centres. The data was analysed for outcome measures.

**Results:** About 16 patients were included in the study, five patients presented with stable angina (31%), three with ACS and in eight it was noted at the index PCI that there was an under expanded stent. Culprit vessel was LAD (44%), LCX (12.5%), RCA (31%), LMS (6.2%) and venous graft (6.2%). The lesion was modified with a 0.9 mm ELCA catheter in 14 (87.5%) while in 2 the catheter was upsized to 2.0 mm. ELCA was performed with saline flush in 12 (75%) and contrast milieu in 4 (25%) cases. The mean total pulses delivered were  $11769.9 \pm 6950.5$  and the maximum fluence was  $80 \text{ mJ/mm}^2$  with a repetition rate of 80 Hz. The mean case time, fluoroscopic time, contrast used, total radiation and skin radiation was  $102.75 \pm 57$  minutes,  $23.56 \pm 19.46$  minutes,  $200.5 \pm 84$  ml,  $8212.38 \pm 7184.9 \mu\text{Gy}^2$  and  $2269.9 \pm 1193.6 \text{ mGy}$ , respectively. NC balloon was used in all cases after ELCA and double coated NC balloon in 9 cases (56%). Successful laser predilatation was achieved by using ELCA alone in 13 cases while in 3 cases RA was required following ELCA with burr size of 1.25 mm and 1.75 mm (2 cases). Following modification of the under expanded stented segment a mean of  $1.5 \pm 0.6$  stents were deployed. The stent length/diameter pre and post laser PCI was  $29 \pm 13.07$  mm,  $3.41 \pm 0.66$  mm and  $31.7 \pm 18.5$  mm,  $3.7 \pm 0.5$  mm, respectively. Following ELCA PCI and stenting the MLA increased from  $2.93 \pm 1.2 \text{ mm}^2$  to  $9.49 \pm 3.08 \text{ mm}^2$ . No major complications occurred during the intervention.

**Conclusion:** This case series demonstrates the safety and efficacy of ELCA used alone or in combination with RA in the treatment of under expanded stents. To our knowledge this application of the RASER technique for this clinical indication is presented here for the first time.

**Key Words:** Excimer laser coronary atherectomy, Rotational atherectomy, Culprit vessel, Stenting.

## INTRODUCTION

An under expanded stent in a heavily calcified lesion is a technical challenge and a therapeutic dilemma. Under expanded stents are associated with instant restenosis, acute and sub acute thrombosis and residual angina. Excimer laser coronary atherectomy (ELCA) has been successfully used in isolated cases.<sup>1</sup> Alternatively, rotational atherectomy (RA) can be used but is less predictable in a newly deployed stents.<sup>2</sup> Our group has previously combined ELCA and RA in non-crossable and non-expandable lesions and for the first time in this abstract present cases where the 'RASER' technique was successfully utilized in treating under-expanded stents.<sup>3</sup> The objectives of this study were to evaluate the efficacy, safety, feasibility and medium term outcome of the use of ELCA either alone or combined with RA (RASER) for management of under expanded stents.

## METHODOLOGY

This was a case series where we identified patients from the hospital computerised database who had undergone ELCA percutaneous coronary intervention (PCI) for under expanded stents from four high volume UK PCI centres (The Royal Bournemouth Hospital, Bournemouth, The Brighton and Sussex University Hospital, Brighton, The University Hospital of North Staffordshire, Stoke-on-Trent and The Belfast Health and Social Care Trust, Belfast, United Kingdom). In all cases the procedure was done with pre-procedural anti-platelet medication as per standard protocol. The procedural details, images, equipment used, complications and follow up details of these 16 patients were

analysed.

## RESULTS

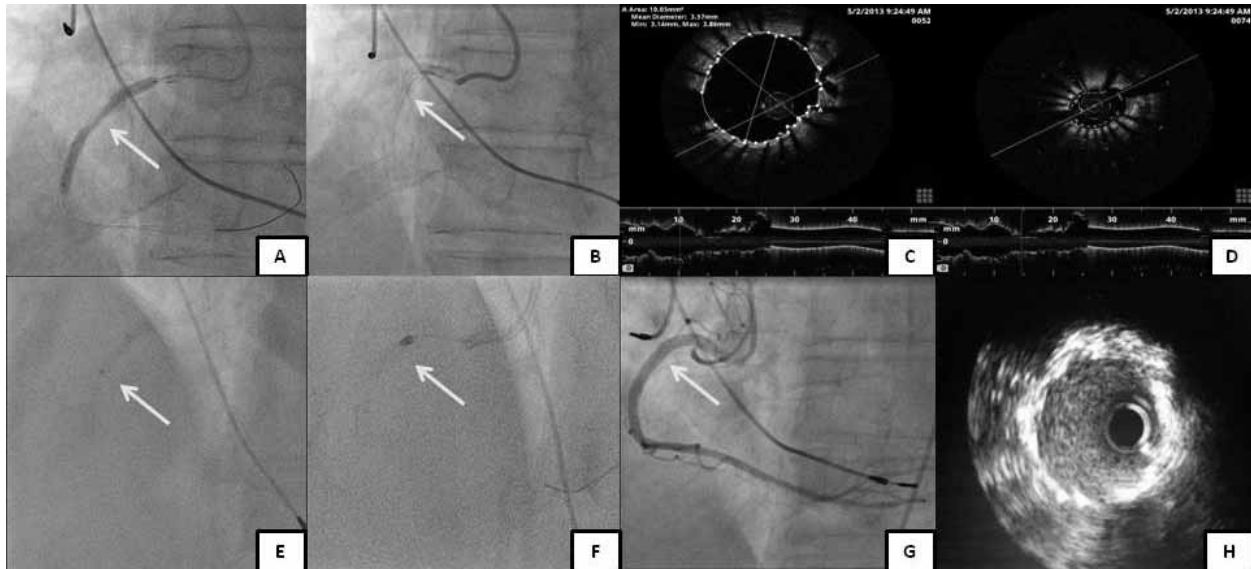
The baseline characteristics of the 16 patients are presented in Table 1. ELCA PCI was performed transradially in 7 cases (44%) whilst the others were performed transfemorally. Culprit lesion was in LAD (44%), LCX (12.5%), RCA (31%), LMS (6.2%) and venous graft to RCA (6.2%). PCI was performed in 8 patients using 6 Fr, 6 using 7 Fr and 2 using an 8 Fr guide. The lesion was modified with a 0.9mm ELCA catheter (Vitresse, Spectranetics/Advanced Interventional Systems) in 14 (87.5%) while in 2 the catheter was upsized to 2.0 mm. ELCA was performed with saline flush in 12 (75%) and contrast milieu in 4 (25%).

The mean total pulse delivered was  $11769.9 \pm 6950.5$  and the maximum fluence was  $80 \text{ mJ/mm}^2$  with a repetition rate of 80 Hz in 94% of cases. The mean case time, fluoroscopic time, contrast used, total radiation and skin radiation was  $102.75 \pm 57$  minutes,  $23.56 \pm 19.46$  minutes,  $200.5 \pm 84$  ml,  $8212.38 \pm 7184.9 \text{ } \mu\text{Gym}^2$  and  $2269.9 \pm 1193.6$  mGy, respectively. NC balloon was used in all cases after ELCA and double coated NC balloon in 9 cases (56%). Successful laser predilatation was achieved by using ELCA alone in 13 cases (balloon predilatation following ELCA) while in 3 cases RA was required following ELCA with burr sizes of 1.25mm (1 case) and 1.75mm (2 cases). Following modification of the under expanded stented segment a mean of  $1.5 \pm 0.6$  stents were deployed. The stent length/diameter pre and post laser PCI was  $29 \pm 13.07\text{mm}/ 3.41 \pm 0.66\text{mm}$  and  $31.7 \pm 18.5\text{mm}/ 3.7 \pm 0.5\text{mm}$ , respectively.

**Table 1: Baseline Variables of Study Population (n=16)**

	VARIABLES	n=16
Demographics	Age, Years	70.4 ± .8
	Male	14 (54%)
	Previous CABG	2 (7.6%)
Risk Factors	Hypertension	10 (62.5%)
	Diabetes	4 (25%)
	Hypercholesterolemia	12 (75%)
	Smoking (current and previous)	8 (50%)
	Family History for IHD	15 (52%)
Left Ventricular Function	Normal	11 (69%)
	Mildly impaired	2 (12.5%)
	Moderately impaired	2 (12.5%)
	Severely impaired	1 (6%)
Culprit Vessel	Left main stem (LMS)	1 (6.2%)
	Left anterior descending (LAD)	7 (44%)
	Circumflex (LCX)	2 (12.5%)
	Right coronary artery (RCA)	5 (31%)
	Venous graft (VG)	1 (6.2%)

**Figure A, B: Undilatable, under-deployed segment (arrow marker).**  
**Figure C, D-OCT image with maximal and minimal luminal diameter in the stented segment.**  
**Figure E, F: The use of ELCA and Rotablation in the under expanded stent segment.**  
**Figure G: Final angiographic picture after ELCA and Rotablation (Raser) followed by stent deployment.**  
**Figure H: IVUS image post stent deployment at the junction of proximal and mid RCA (arrow marked site in Figure G)**



Following ELCA PCI and stenting the minimum lumen area (MLA) increased from  $2.93 \pm 1.2 \text{ mm}^2$  to  $9.49 \pm 3.08 \text{ mm}^2$  (Figure 1). No major complications occurred during the intervention. Mean follow up data of 12 out of 16 was available for  $23.5 \pm 16$  months during which time one patient developed in-stent restenosis (8.3%) and one experienced sub-acute stent thrombosis (8.3%) following two months.

## DISCUSSION

Debulking to facilitate dilation of calcified lesions prior to stent implantation can be achieved usually by using RA, ELCA or adjunctive techniques.<sup>1,2,4</sup> Deployment of a stent prior to recognising that the lesion is non dilatable leads to an unexpandable, under-deployed stent. Despite the use of high pressure post dilatation these segments can be highly resistant to balloon dilatation. ELCA has been used in under-deployed stent in an attempt to vaporize the atherosclerotic plaque by the acoustic mechanical effect of the rapidly exploding bubble and to facilitate expansion of the under-deployed stented segment.<sup>1,3</sup> ELCA consists of a thin, flexible fibre-optic catheter connected to an external laser-generating source, with the tip of the catheter system emitting pulses of laser energy. The absorption of the laser energy by blood and saline leads to fast vapour bubble expansion and implosion intraluminally, leading to the fragmentation of superficial fibrocalcific deposits, explosive dilation and vessel expansion.<sup>5</sup> ELCA increased lumen by both atheroablation and forced vessel expansion facilitating

dilatation of under-deployed stent.<sup>6</sup> ELCA PCI for under-expanded stents would require high energy ELCA and in this cohort mean total pulses delivered was  $11769.9 \pm 6950.5$ . Moreover, in 94% of the cases the maximum fluence/repetition ( $80 \text{ mJ/mm}^2/80\text{Hz}$ ) were used. The use of saline infusion at the time of laser pulse delivery has been shown to reduce vessel wall injury due to acoustic damage.<sup>7</sup> There are case reports of the use of contrast and high energy ELCA to facilitate expansion of under-deployed stent.<sup>1</sup> The use of contrast leads to larger sized bubbles and may lead to significant vessel injury. However, in a stented segment the vessel wall injury due to large sized vapour bubbles might be minimum especially after stent endothelialisation. The ELLEMENT registry demonstrated the feasibility, safety and efficacy of contrast milieu, ELCA to facilitate the expansion of undilatable stents.<sup>8</sup> In this cohort, ELCA PCI was performed with contrast milieu in four patients without major complications.

There are isolated published case reports of the use of RA to abrade the stent and underlying calcification with subsequent drug eluting stent implantation (stentablation).<sup>2,9</sup> RA leads to differential cutting of the inelastic tissue. The lumen improvement after RA is due to tissue ablation. Particulate debris of calcium and metal from RA of a deployed stent is generally under 5 to 15 micrometer and is cleared by the reticuloendothelial system.<sup>10</sup> In this series we used combination of ELCA and RA (RASER) effectively in 3 cases. RASER PCI leads to atheroablation, fibrocalcific fragmentation, vessel expansion followed by tissue and

stent ablation.<sup>11</sup> To our knowledge this application of the RASER technique for this clinical indication is presented here for the first time. Adequate preparation of the lesion following ELCA and prior to stent deployment is important and this cohort in all cases a NC balloon was used for lesion preparation. In 56% of our cases a double coated balloon was used. Following the RASER technique, (3 cases) drug eluting stents were successfully deployed in all cases without major complication. Furthermore, the mean MLA increased from  $2.93 \pm 1.2 \text{mm}^2$  to  $9.49 \pm 3.08 \text{mm}^2$ . Procedure related ischemia, dissection, no re-flow or haemodynamic compromise was not recorded in any of the 16 cases. In all cases excellent final angiographic and IVUS results were achieved. Moreover, 83% of the patients had good medium term outcome for the procedure. Procedural success and outcome measures of this cohort is comparable to results from the ELLEMENT registry.<sup>8</sup>

## CONCLUSION

This case series demonstrates the safety and efficacy of ELCA used alone or in combination with RA (RASER) in the treatment of under expanded stents. Furthermore, ELCA can be performed with saline or contrast milieu.

## REFERENCES

1. Egred M. A novel approach for under-expanded stent: excimer laser in contrast medium. *J Invasive Cardiol* 2012;24(8):161-3.
2. Lee S, Park KW, Kim HS. Stentablation of an underexpanded stent in a heavily calcified lesion using rotational atherectomy. *J Cardiovasc Med (Hagerstown)* 2012;13(4):284-8.
3. Fernandez JP, Hobson AR, McKenzie D, Shah N, Sinha MK, Wells TA, et al. Beyond the balloon: excimer coronary laser atherectomy used alone or in combination with rotational atherectomy in the treatment of chronic total occlusions, non-crossable and non-expansile coronary lesions. *Eurointervention* 2013;9(2):243-50.
4. Bilodeau L, Fretz EB, Taeymans Y, Koolen J, Taylor K, Hilton DJ. Novel use of a high energy excimer laser catheter for calcified and complex coronary artery stenosis. *Catheter Cardiovasc Interv* 2004;62(2):155-61.
5. Mintz GS, Kovach JA, Javier SP, Pichard AD, Kent KM, Popma JJ, et al. Mechanisms of lumen enlargement after excimer laser coronary angioplasty. An intravascular ultrasound study. *Circulation* 1995;92(12):3408-14.
6. Rana OA, Talwar S, O'Kane P. Excimer coronary laser atherectomy during percutaneous coronary intervention of complex lesions: balloon failures, chronic total occlusions and under-expanded stents. In: Topaz O, editor. *Lasers in cardiovascular interventions*. New York: Springer publishers; 2015.
7. Deckelbaum LI, Natarajan K, Bittl JA, Rohlf K, Scott J, Chisholm R, et al. Effect of intracoronary saline infusion on dissection during excimer laser coronary angioplasty: a randomised trial. *J Am Coll Cardiol* 1995;26(5):1264-9.
8. Latib A, Takagi K, Chizzola G, Tobis J, Ambrosini V, Niccoli G, et al. Excimer laser lesion modification to expand non-dilatable stents: The ELLEMENT registry. *Cardiovasc Revasc Med* 2014;15(1):8-12.
9. Akin I, Pohlmann S, Nienaber CA, Ince H. A different way of coronary lesion preparation: stentablation and rotastenting. *Clin Med Insights Cardiol* 2012;6:53-6.
10. Tomey MI, Kini AS, Sharma SK. Current status of rotational atherectomy. *J Am Coll Cardiol Intv* 2014;7(4):345-53.
11. McKenzie DB, Talwar S, Jokhi PP, O'Kane PD, Osherov A, Strauss B, et al. How should I treat severe coronary artery calcification when it is not possible to dilate a balloon or deliver a RotaWireTM? *Eurointervention* 2011;6(6):779-83.