

## FREQUENCY OF LEFT VENTRICULAR THROMBUS AMONG PATIENTS WITH ACUTE CORONARY SYNDROME

Asfandyar Ahmad<sup>1</sup>, Amber Ashraf<sup>2</sup>, Noorul Hadi<sup>3</sup>, Javid Shah<sup>4</sup>

<sup>1-4</sup>Department of Cardiology, Khyber Teaching Hospital, Peshawar - Pakistan

Address for Correspondence:

**Amber Ashraf,**

Department of Cardiology, Khyber Teaching Hospital, Peshawar - Pakistan

Emails: cardiologistamber@hotmail.com

Date Received: September 14, 2017

Date Revised: November 12, 2017

Date Accepted: December 17, 2017

### Contribution

AA conceived the idea and drafted the manuscript. NUH & JS collected and analyzed the data. AA did the critical review. All authors contributed equally to the submitted manuscript.

### All authors declare no conflict of interest.

This article may be cited as: Ahmad A, Ashraf A, Hadi N, Shah J. Frequency of left ventricular thrombus among patients with acute coronary syndrome. Pak Heart J 2018;51 (01): 49-53

### ABSTRACT

**Objective:** To determine the frequency of left ventricular thrombus among patients with Acute Coronary Syndrome presenting to cardiology department, Khyber Teaching Hospital, Peshawar .

**Methodology:** This study was conducted at Department of Cardiology, Khyber teaching hospital, Peshawar from 20<sup>th</sup> January to 20<sup>th</sup> July, 2016. It was a descriptive cross sectional study. Patients with new-onset ACS were included in the study, subjected to 1-hourly serial ECGs. Troponin-I levels were sent at 0, 6 and 12 hours after admission and echocardiography was performed after stabilization.

**Results:** Out of 404 selected ACS patients, 8 patients (1.98%) had an LV-thrombus. LV-thrombus was found in 0.74% in patients with unstable angina, 0.70% in NSTEMI, 2.7% in thrombolysed STEMI patients and 26.6% in non-thrombolysed STEMI patients.

**Conclusions:** Left ventricular thrombus is a common finding in patients with acute coronary syndrome and echocardiography should be performed as soon as possible in patients with acute coronary syndrome.

**Key Words:** Left ventricular thrombus, Echocardiography, Contrast enhanced imaging, Anticoagulation.

## INTRODUCTION

Cardiovascular disease remains the leading cause of death in Pakistan.<sup>1</sup> One of the most feared complications is the occurrence of thromboembolic events (mostly cerebrovascular accidents) due to left ventricular (LV) thrombus formation.<sup>2</sup> The risk of LV thrombus formation is highest during the first 3 months following acute myocardial infarction, but the potential for cerebral emboli persists in the large population of patients with chronic LV dysfunction.<sup>3,4</sup> Since these thromboembolic events are usually unheralded by warning signs of transient cerebral ischemia, the only truly satisfactory medical approach is adequate management of these high risk groups. The reported frequency of LV thrombus formation after an event of acute coronary syndrome is 19% by SarrM et al and 8.8% by Delewi R et al<sup>5,6</sup>. In one study conducted at Gomal medical college left ventricular thrombus was found in 9(7.56%) patients, 6 patients with anterior myocardial infarction, 2 with anterolateral and 1 with antero-inferior myocardial infarction.<sup>7</sup> In another study conducted at Ayub teaching hospital 34.1% of the patients with acute anterior wall M.I had the LV-thrombus.<sup>8</sup> In a study at Liaquat university hospital, LV-thrombus was found in 17.86% of the patients with acute anterior wall M.I.<sup>9</sup>

Two dimensional non-contrast enhanced TTE is the technique used most often for assessing the presence, shape and size of an LV mural thrombus. When the thoracic anatomy of the patient allows sufficient visualization of the heart, two dimensional echocardiography provides excellent specificity (85–90%) and sensitivity (95%) in detecting LV thrombus but an overall sensitivity of 33%-40% because of various factors leading to poor echo windows formation.<sup>3</sup> CT scanning provides about the same specificity and sensitivity as two dimensional TTE in the identification of LV. Cardiac magnetic resonance imaging (CMR) with contrast (delayed enhancement (DE)) has significantly better accuracy than TTE and TOE for the diagnosis of LV thrombus. Delayed-enhancement cardiac magnetic resonance imaging (DE-CMR) i-e contrast CMR has reported sensitivity of 88% with specificity of more than 90% for LV-thrombus.<sup>10,11</sup> The contrast-enhanced echocardiography has the sensitivity and specificity of almost DE-CMR.<sup>4</sup>

Data regarding the benefit of heparin treatment in patients with documented LV thrombus on echocardiography during the first 2 weeks are somewhat conflicting, leading to a belief that there may be a benefit, at least in the short term for anticoagulation.<sup>12</sup> A 1993 meta-analysis included 11 studies of 856 patients who had an anterior myocardial infarction; the odds ratio (OR) for an embolic event was 5.5 (95% CI 3.0 to 9.8). The meta-analysis included seven studies with 270 patients that included data on the relationship between anticoagulation for 6 months and embolisation. Although all seven studies presented data suggesting that systemic

anticoagulation reduces embolic complications, this trend reached significance only in three trials. When pooling the data, anticoagulation compared with no anticoagulation was associated with a reduction in the rate of embolization.<sup>13</sup>

Based on these data, both current European Society of Cardiology and American College of Cardiology/American Heart Association guidelines recommend vitamin K antagonist therapy in patients with an LV thrombus after myocardial infarction, If there is contraindication to use of warfarin or some problem in compliance as well as monitoring, then other new oral anticoagulants should be prescribed initially for 3 months and then planned further according to follow up echoes.<sup>14</sup> The mainstay of treatment for LV-thrombus is anticoagulation. Data from the GISSI-3 database, including more than 8000 patients, showed no reduced incidence of thrombus formation in patients who received Lisinopril.<sup>15</sup>

## METHODOLOGY

This cross sectional study was conducted at Cardiology Department Khyber Teaching Hospital Peshawar (KTH). All the patients presenting with Acute Coronary Syndrome, referred from emergency department or outpatient department to the Cardiology Department of KTH Peshawar, were included in the study regardless of the age and gender. It was a 6 months study from 20<sup>th</sup> January to 20<sup>th</sup> July, 2016.

The study was conducted after approval from hospitals ethical and research committee. All patient presenting with acute coronary syndrome were included in the study through out-patient-department and Accident-and-Emergency department and were admitted in the cardiology ward/coronary care unit for further evaluation. The purpose and benefits of the study were explained to the patients and a written informed consent was obtained.

All patients were subjected to thorough clinical history. A detailed clinical examination with 1-hourly ECG and transthoracic echocardiography done in all patients to detect LV thrombus. Troponin-I levels were sent at 0, 6 and 12-hours after admission.

All these observations and measurements were performed under supervision of a team of cardiologists and all the patients were managed as per ward protocols under supervision of same team of cardiologists and strict inclusion and exclusion criteria were followed so that to avoid any bias in data.

Data collected, was analyzed using SPSS version-20. Frequency and percentage was calculated for categorical variables like gender and LV thrombus. LV thrombus was stratified among age and gender to see the effect modifications. All results were presented in the form of tables and graphs. Apart from the main objective of finding frequency of LV-thrombus amongst all the patients, its

frequency within each type of Acute coronary syndrome and its relation to thrombolytic therapy was also identified.

## RESULTS

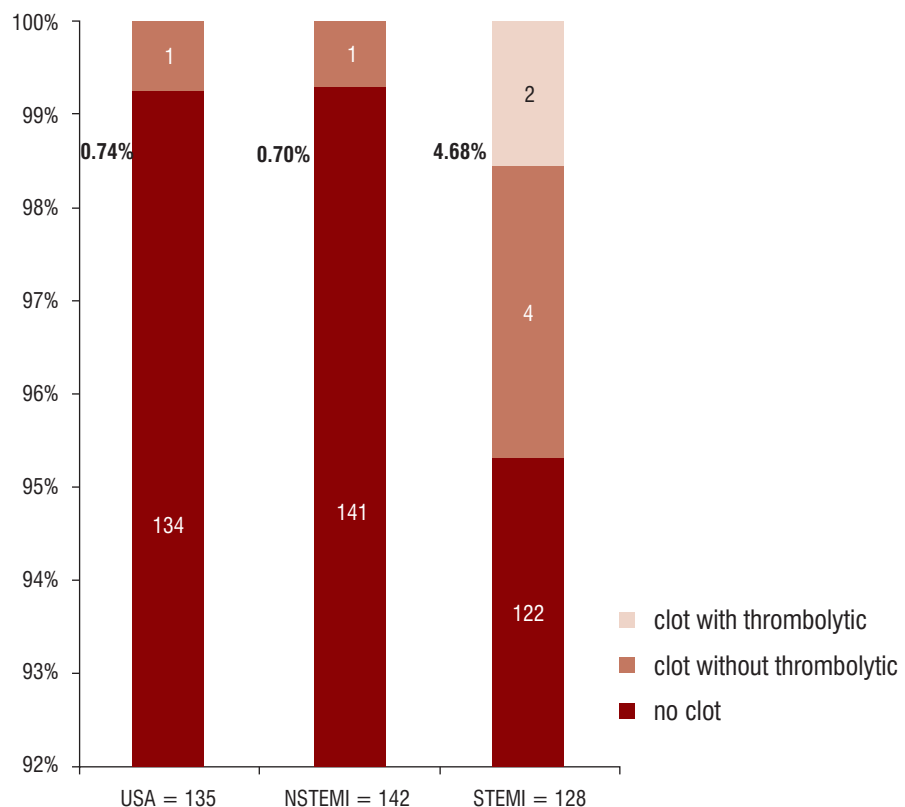
About 992 patients were admitted to Cardiology Department during the course of the study. Out of them, total of 404 patients were selected for the study who presented with acute coronary syndrome (ACS). That makes about 41.23% of the total admissions during that time period. Out of them, 55.20% (223) patients were male. Mean age of all the patients was  $59.32 \pm 11.54$  years. Mean Age of the male patients was  $59.88 \pm 11.12$  years. About 181 patients were females which makes about 44.80% of the total ACS admissions. Mean age of male patients was  $59.88 \pm 11.12$  years. About 181 patients were females which makes about 44.80% of the total ACS admissions. Mean age of female patients was  $59.04 \pm 12.02$  years. Six patients died before stabilization for echocardiography to be performed. In the

total 404 patients presenting with ACS, 1.98% (8) patients had LV-Thrombus, 135 patients presented with unstable angina which makes the percentage of 33.4% of total patients of acute coronary syndrome. Only one of them had an LV-Thrombus on echocardiography which makes 0.74% of the patients with unstable angina and 0.24% of the patients with acute coronary syndrome, 142 patients presented with NSTEMI which makes the percentage of 35.1% of the total acute coronary syndrome admissions. Only one (0.70%) of them had LV-thrombus on routine echocardiography. Of 31.68% (128) patients presenting with STEMI LV-thrombus was detected in 4.68% (6) patients. About 69.53% (89) patients presented with STEMI involving anterior territory of left ventricle, either alone or in combination with lateral or septal territory. Total of 6.7% (6) patients with anterior-territory-involving-STEMI-admissions had an LV-Thrombus on echocardiography. Out of 89, 74 patients were thrombolysed (83.14%) while 15 patients were considered late for thrombolytic therapy (16.85%). Two of 74

**Table 1: Distribution of LV-Thrombus Among Patients with Acute Coronary Syndrome (n=404)**

LV-thrombus	Frequency (n)	Percentage (%)
Yes	8	1.98%
No	396	98.02%
Total	404	100%

**Figure 1: Distribution of LV-Clot Among Different Types of Acute Coronary Syndromes (n=404)**



thrombolysed patients had LV-clot (2.7 % of the thrombolysed patients) which makes about one-third of the STEMI patients with LV-clot while it makes 25% of the patients with LV-thrombus presenting with any acute coronary syndrome. In non thrombolysed patients, 4 out of 15 patients had LV-clot (26.6% of the non-thrombolysed patients) which makes two-thirds of STEMI patients with LV-clot and it makes 50% of the patients with LV-clot presenting with any ACS.

The number of patients with inferior wall STEMI, either alone or in combination with RV-Infarct, posterolateral wall infarct, etc., was 31 (7.6% of total ACS admissions and 24.2% of STEMI admissions). None of them had an LV-thrombus. None of the eight patients with lateral STEMI (1.98% of the ACS admissions while 6.25% of total STEMI admissions) had LV thrombus.

The frequency of LV-clot was clearly more in STEMI patients with anterior territory involvement (75%) and in those in whom thrombolytic therapy was either not indicated or considered late (75%).

## DISCUSSION

In this study, we enrolled 410 patients out of which 6 patients died before echocardiographic evaluation. So a total of 404 patients with acute coronary syndrome were evaluated. Among patients with acute coronary syndrome a total of 1.98% (n=8) patients were found to have an LV-Thrombus.

The reported frequency of LV thrombus formation after an event of acute coronary syndrome is 19% by Sarr M et al and 8.8% by Delewi R et al.<sup>5,6</sup> The cause of high frequency reported by Sarr M et al is that they used CMR for detection of LV thrombus in their study which is highly sensitive compared to Echocardiography. In one study conducted at Gomal Medical College left ventricular thrombus was found in 9(7.56%) patients. In this study serial echocardiographies were done on day 1, 3 and 5 for LV thrombus while we did only one echo examination. In another study conducted at Ayub Teaching Hospital 34.1% of the patients had the LV-thrombus but they studied patients admitted with anterior wall MI.<sup>7,8</sup> In a study at Liaquat University Hospital, LV-thrombus was found in a much higher percentage of patients (17.86%) of the patients with acute anterior wall M.I because they did follow up echos for 6 months unlike our study where we did only one echo during admission.<sup>9</sup>

Left ventricular thrombus was much common in STEMI patients involving anterior territory (6 out of 8 patients, i.e 75%). It was much common in patients in whom no thrombolytic therapy was given (4 non-thrombolysed STEMI + 1 unstable angina + 1 NSTEMI=6 out of 8 patients, i.e 75%). Although in the side study of GISSI-2, no difference was found in frequency among thrombolysed and non-thrombolysed patients and previous pooled data from 6

studies by Paul vaitkus and Barnathan showed only a good trend towards use of previous thrombolytic therapy, this study clearly showed a benefit in thrombolysed patients.<sup>13,16</sup>

Although the LV-thrombus was found in a single patient with unstable angina, there was an area of akinesia on echocardiography which showed a probability of an old M.I which went unnoticed by the patient. This implies further studies on frequency among patients with unstable angina and no regional wall motion abnormalities. The current guideline clearly suggests the use of anticoagulation for 3-6 months in the case of an LV-thrombus complicating an ACS but warns against more prolonged course with dual antiplatelet therapy because of the risk of major bleeding. The surgical option for removal of a mobile, pedunculated clot needs further studies to be clearly indicated in these circumstances but has shown much benefit. Perhaps in near future, aspiration of such thrombi by aspiration catheter may gain some attention.

## CONCLUSION

LV thrombus is commoner in patients with acute anterior wall STEMI who are not thrombolysed because these patients show much more myocardial injury and area of regional wall motion abnormality favoring the formation of a blood clot. The presence of LV thrombus should be kept in mind in patients with unstable angina and NSTEMI who exhibit thromboembolic phenomenon and meticulous search should be made to rule out their presence with echocardiography as soon as possible.

## REFERENCES

1. Masood A, Akhthar N. Review and guidelines for the management of patients with chronic therapeutically refractory angina. *Pak J Cardiol*. 2006;7:6-15.
2. Solheim S, Seljeflot I, Lunde K. Frequency of left ventricular thrombus in patients with anterior wall acute myocardial infarction treated with percutaneous coronary intervention and dual antiplatelet therapy. *Am J Cardiol* 2010;106:197–200.
3. Weinsaft JW, Kim HW, Crowley AL. LV thrombus detection by routine echocardiography: insights into performance characteristics using delayed enhancement CMR. *J Am Coll Cardiol* 2011;4:702–12.
4. Weinsaft JW, Kim RJ, Ross M. Contrast-enhanced anatomic imaging as compared to contrast-enhanced tissue characterization for detection of left ventricular thrombus. *J Am Coll Cardiol* 2009;2:969–79.
5. Sarr M, Ba DM, Ndiaye MB, Bodian M, Jobe M, Kane A et al. Acute coronary syndrome in young Sub-Saharan Africans: A prospective study of 21 cases. *BMC cardiovascular disorders* 2013;13(1):118.

6. Delewi R, Nijveldt R, Hirsch A, Marcu CB, Robbers L, Hassell ME et al. Left ventricular thrombus formation after acute myocardial infarction as assessed by cardiovascular magnetic resonance imaging. *Eur J Radiol* 2012;81(12):3900-3904.
7. Khan M.R, Khan H, Marwat M. Frequency of left ventricular thrombus in ST-elevation myocardial infarction on echocardiography. *Gomal J Med Sci* 2013;11:129-132.
8. M. Jalal-ud-din, Raheel J.J, Asfandyar Q, et al. Left ventricular thrombus in patients with acute anterior wall myocardial infarction. *J Ayub Med Coll* 2014;26(4): 491-495.
9. Rathi N, Maheshwar N, Kumari D, et al. Left ventricular thrombus in acute myocardial infarction. *Pak Heart J* 2009;42(1-2):9-13.
10. Srichai MB, Junor C, Rodriguez LL, et al. Clinical, imaging, and pathological characteristics of left ventricular thrombus: a comparison of contrast enhanced magnetic resonance imaging, transthoracic echocardiography, and transesophageal echocardiography with surgical or pathological validation. *Am Heart J* 2006;152:75–84.
11. Dymarkowski S, Volders W, et al. Visualization of ventricular thrombi with contrast-enhanced magnetic resonance imaging in patients with ischemic heart disease. *Circulation* 2002;106:2873–6.
12. Weinsaft JW, Kim RJ, Ross M, et al. Contrast-enhanced anatomic imaging as compared to contrast-enhanced tissue characterization for detection of left ventricular thrombus. *JACC Cardiovasc Imaging* 2009;2:969–79.
13. Vaitkus PT, Barnathan ES. Embolic potential, prevention and management of mural thrombus complicating anterior myocardial infarction: a meta-analysis. *J Am Coll Cardiol* 1993;22:1004–9.
14. Hein Heidbuchel, Peter Verhamme, Marco Alings, et al. EHRA Practical Guide on the use of new oral anticoagulants in patients with non-valvular atrial fibrillation: executive summary. *Eur heart j* 2016; 34(11):791-5.
15. Chiarella F, Santoro E, Domenicucci S, et al. Predischarge two-dimensional echocardiographic evaluation of left ventricular thrombosis after acute myocardial infarction in the GISSI-3 study. *Am J Cardiol* 1998;81:822–7.
16. Vecchio C, Chiarella F, Lupi G, et al. Left ventricular thrombus in anterior acute myocardial infarction after thrombolysis. A GISSI-2 connected study. *Circulation* 1991;84:512–19.